

LECTURE NOTES

For Health Science Students

<https://ismailpages.wordpress.com/>
<https://ismailawabdi.wordpress.com/health/>

Ophthalmology



Dereje Negussie, Yared Assefa, Atotibebu Kassa, Azanaw Melese

University of Gondar

In collaboration with the Ethiopia Public Health Training Initiative, The Carter Center,
the Ethiopia Ministry of Health, and the Ethiopia Ministry of Education

2004



Funded under USAID Cooperative Agreement No. 663-A-00-00-0358-00.

Produced in collaboration with the Ethiopia Public Health Training Initiative, The Carter Center, the Ethiopia Ministry of Health, and the Ethiopia Ministry of Education.

Important Guidelines for Printing and Photocopying

Limited permission is granted free of charge to print or photocopy all pages of this publication for educational, not-for-profit use by health care workers, students or faculty. All copies must retain all author credits and copyright notices included in the original document. Under no circumstances is it permissible to sell or distribute on a commercial basis, or to claim authorship of, copies of material reproduced from this publication.

©2004 by Dereje Negussie, Yared Assefa, Atotibebu Kassa, Azanaw Melese

All rights reserved. Except as expressly provided above, no part of this publication may be reproduced or transmitted in any form or by any means, electronic or mechanical, including photocopying, recording, or by any information storage and retrieval system, without written permission of the author or authors.

This material is intended for educational use only by practicing health care workers or students and faculty in a health care field.

PREFACE

This lecture note will serve as a practical guideline for the hard-pressed mid-level health workers. We hope that it will be a good introduction to eye diseases for health science students working in Ethiopia.

There are so many books about eye diseases available but hardly any, which are written from the perspective of Ethiopia, where more blind are live.

The lecture note is basically focused on the community as well as clinical ophthalmology to introduce the students on the common causes and burden of blindness and their preventive aspect. So it is written for students who are intended to see patients and need to recognize each disease and recommend possible treatment. When looking at a patient with eye disease, the most important skill is to be able to recognize the appearance of each particular disease.

In the management of diseases which are beyond their scope are recommended to refer as early as possible. They shouldn't urge to start to manage such patients at their level. Their main role is to pick problems early and to have an active role in the prevention of blindness. Selected pictures are used to illustrate some anatomical parts and common eye diseases to make note easier and understandable.

There are several encouraging signs that there is an increasing awareness of the challenge of treatable and preventable blindness throughout the world. Our country is forming prevention of blindness to try to look realistically at the problem locally. NGO's and the government are highly devoted to treat and prevent major cause of blindness in the country specially cataract and trachoma.

In spite of all this, the number of avoidably blind people in Ethiopia continues to increase faster than the population.

ACKNOWLEDGEMENT

The development of this lecture note has gone through series of individual works, writing and revisions. We would like to express our appreciation to The Carter Center, Atlanta Georgia for funding the activities in the development of this lecture note all the way through.

We would like to thank Gondar University for helping us with different material in order to make this note feasible.

Reviewers that highly contributed to the development of this material using their valuable time and experience include

1. Dr. Yonas Tilahun, Assistant Professor in Ophthalmology, AAU-MF.
2. Dr. Yilikal Adamu, Honorary Assistant Professor in Ophthalmology, AAU-MF
3. Dr. Yeneneh Mulugeta, Assistant Professor in Ophthalmology, Jimma University
4. Dr. Zeki Abdurazik, Assistant professor in Surgery, Gondar University

At last but not least we would like to convey special appreciation for the finalization of the material at National reviewer level by using his valuable time

Dr. Abebe Bejiga , Associate professor in ophthalmology , AAU-MF

TABLE OF CONTENTS

<u>TOPIC</u>	<u>PAGE</u>
PREFACE	i
ACKNOWLEDGEMENT	ii
TABLE OF CONTENT	iii
LIST OF FIGURES AND COLOR PLATES	iv
LIST OF TABLES	v
ABBREVIATION AND ACRONYMS	vi
INTRODUCTION	1
UNIT ONE	
BASIC ANATOMY AND PHYSIOLOGY OF THE EYE	3
UNIT TWO	
BASIC EXAMINATION OF THE EYE	17
UNIT THREE	
EXTERNAL EYE DISEASES	28
UNIT FOUR	
DIFFERENTIAL DIAGNOSIS OF RED EYE	35
UNIT FIVE	
COMMUNITY OPHTHALMOLOGY	45
UNIT SIX	
EYE INJURIES	67
UNIT SEVEN	
SYSTEMIC DISEASE AND THE EYE	71
APPENDIX	78
REFERENCES	81

3. LIST OF FIGURES AND COLOR PLATES

- Figure 1.1: The structure of the eye lids and conjunctiva
- Figure 1.2: The lacrimal apparatus
- Figure 1.3: Components and origin of tear film
- Figure 1.4: The basic structure of the eye to show its three layers
- Figure 1.5: Enlarged views of the angle of anterior chamber
- Figure 5.1: Refraction in normal eye
- Figure 5.2: Refraction in a myopic eye
- Figure 5.3: Refraction in a hypermetropic eye
- Figure 5.4: Refraction by an astigmatic eye
- Color plate .1. Pterygium
- Color plate .2. Corneal foreign body
- Color plate .3. Mature cataract
- Color plate .4. Mild trachoma with follicle and papilla
- Color plate .5. Severe trachoma with follicle and papilla
- Color plate .6. Moderate trachoma with follicle and papilla
- Color plate .7. Large follicle and papilla
- Color plate .8. Conjunctival scarring in the upper conjunctiva
- Color plate .9. Corneal vascularization with scar
- Color plate .10. Acute iridocyclitis
- Color plate .11. Bitot's spots with conjunctival xerosis
- Color plate .12. Blepharitis
- Color plate .13. Penetrating eye injuries with scleral laceration
- Color plate .14. Bacterial conjunctivitis
- Color plate .15. Keratitis
- Color plate .16. Congenital glaucoma
- Color plate .17. Left exotropia
- Color plate .18. Ophthalmic Herpes Zoster

List of tables

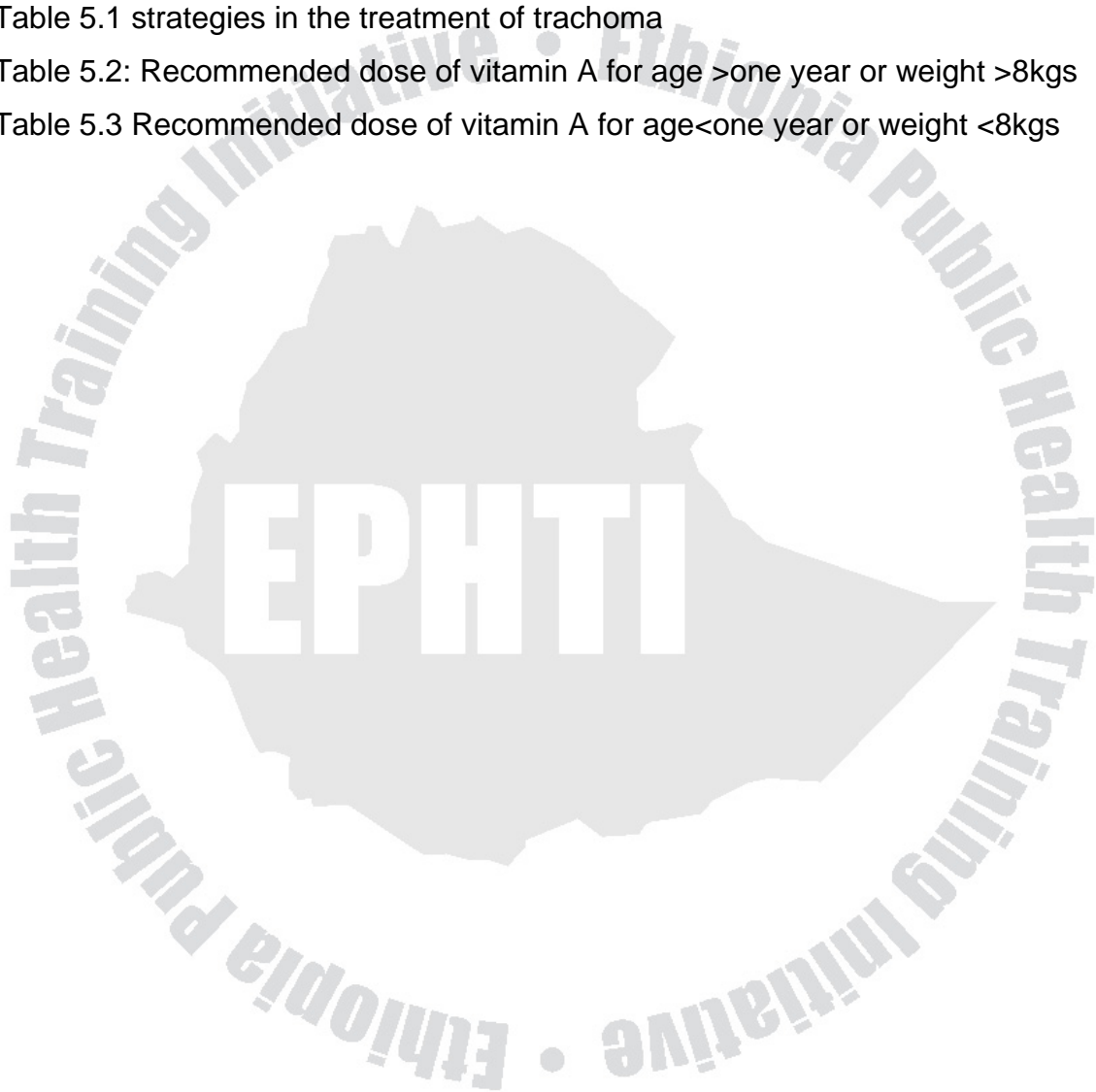Table 1.1: Revision of extra ocular muscle innervations and their actions

Table 4.1: Summary of Differential Diagnosis of red eye

Table 5.1 strategies in the treatment of trachoma

Table 5.2: Recommended dose of vitamin A for age >one year or weight >8kgs

Table 5.3 Recommended dose of vitamin A for age <one year or weight <8kgs



5. Abbreviation and acronyms

AIDS	- Acquired Immune Deficiency syndrome
CF	-Counting finger
CMV	- Cytomegalovirus
CN	-Cranial nerve
CO	- Corneal opacity
ELISA	- Enzyme linked immuno sorbent assay
HM	- Hand motion
HIV	- Human immune deficiency virus
IOP	-Intra ocular pressure
LP	-Light perception
NLP	- No light perception
OD	- Oculus Dexter(right eye)
OS	- Oculus Sinister (left eye)
OU	- Oculus unita (both eye)
TF	- Trachomatous follicle
TI	-Trachomatous intense
TOD	- Tension of Oculus Dexter
TOS	- Tension of Oculus Dexter
TS	- Trachomatous scarring
TT	- Trachomatous trichiasis
V/A	- Visual acuity
VOD	- Vision of Oculus Dexter
VOS	- Vision of Oculus Sinister

INTRODUCTION

The eye is the most amazing and complex structure in the body .The two eyes provide about half the total sensory input from the entire body into the brain. The eye is sensitive to trauma, infection or inflammation that may end up in blindness. Just as the blind spot is neglected by the brain, about 45million people in the world who are blind are largely neglected by medical science and technology, and by the caring professionals; of this 80% is preventable. The situation in Ethiopia is similar with prevalence of blindness being about 1.5% and an estimated around 1.05 million blind people. .Blindness has, directly or indirectly, social as well as economical impact. The causes are multifactorial. In order to address these multifactorial causes, all rounded and effective approach is needed.

Above all there are few ophthalmologists and other ophthalmic workers in relation to population. So the need for skilled man- power that will involve specially at preventable level is undoubted. For this, problem oriented training is mandatory in order to overcome ophthalmic health problems in the country. The care taker should be aware of its sensitivity. This can be done by early management at the first level of health institute or by appropriate referral

There are many reference books about ophthalmic diseases but most are not written with regard to our country's situation where most blind people live. To alleviate this problem, Ophthalmology Department of Gondar University has got a full support from carter center. Thus, this teaching material was prepared. It was tried to focus on common ophthalmic problems and major causes of blindness so that this document will serve as a practical guideline for mid-level health workers. The lecture note will give the students pertinent knowledge and practice about prevention of blindness. It contains seven chapters.

Each chapter contains:

1. Objectives at the beginning of the chapters which are intended to guide the students in their study.
2. The body with detail notes
3. Exercises related to it and suggested references.



UNIT ONE

BASIC ANATOMY AND PHYSIOLOGY OF THE EYE

- 1.1 PROTECTION OF THE EYE
- 1.2 THE EYE BALL
- 1.3 BLOOD SUPPLY, LYMPHATIC DRAINAGE AND INNERAVATION OF THE EYE
- 1.4 EXTRA OCULAR MUSCLES

Objective

1. To give a clear description on the anatomy and physiology of the eye.
2. Having the basic idea will help to have a better understanding on the pathology of specific part of the eye.
3. At the end of this course, students are expected to know basic anatomy and physiology of the eye.

1.1. THE PROTECTION OF THE EYE

A - Eye Lids

It has the following parts

I. Skin - has three important features

- Thinnest, more elastic and mobile than skin else where in the body
- Little or no subcutaneous fat under the skin makes it a good source of skin graft
- Has an extremely good blood supply that is why wound heals well and quickly.

II. Muscles

Orbicularis oculi muscle

- Important for closure of eye lid

- Innervated by facial (7th cranial) nerve

Levator Palpebrae

- Elevator of eye lid.
- Innervated by Oculomotor (3rd cranial) nerve

Muller's muscle

- Help to retract the upper eye lid
- Innervated by cervical sympathetic nerve.

III. Tarsal plates

- Are composed of dense fibrous tissue
- Keep the eye lids rigid and firm
- Contain meibomian glands, which open at lid margin, and makes oily secretion that forms a part of corneal tear film.

B. Conjunctiva

It is a thin mucous membrane which lines the inner surface of the eye lid and outer surface of the eye ball.

The main function of the conjunctiva is to protect the cornea.

- During opening and closure of the eyelids, it lubricates the cornea with tears.
- The conjunctiva also protects the exposed parts of the eye from infection because it contains lymphocytes and macrophages to fight infections.
- Mucin from goblet cells has wetting effect of tear film

It has three parts:

I. Tarsal Conjunctiva

- The part lining in the inner aspect of the eye lid
- Firmly attached to the underlying tarsal plate

II. Bulbar Conjunctiva

- The part lining the eye ball
- Loosely attached to the underlying sclera

III. Fornix

-Part in which the tarsal and bulbar conjunctivas are continuous.

The conjunctival epithelium is continuous with the corneal epithelium at the margin of the cornea, which is called limbus. Conjunctiva contains many small islands of lymphoid tissue especially in the fornix.

Gray line is a mucocutaneous junction of the skin and conjunctiva.

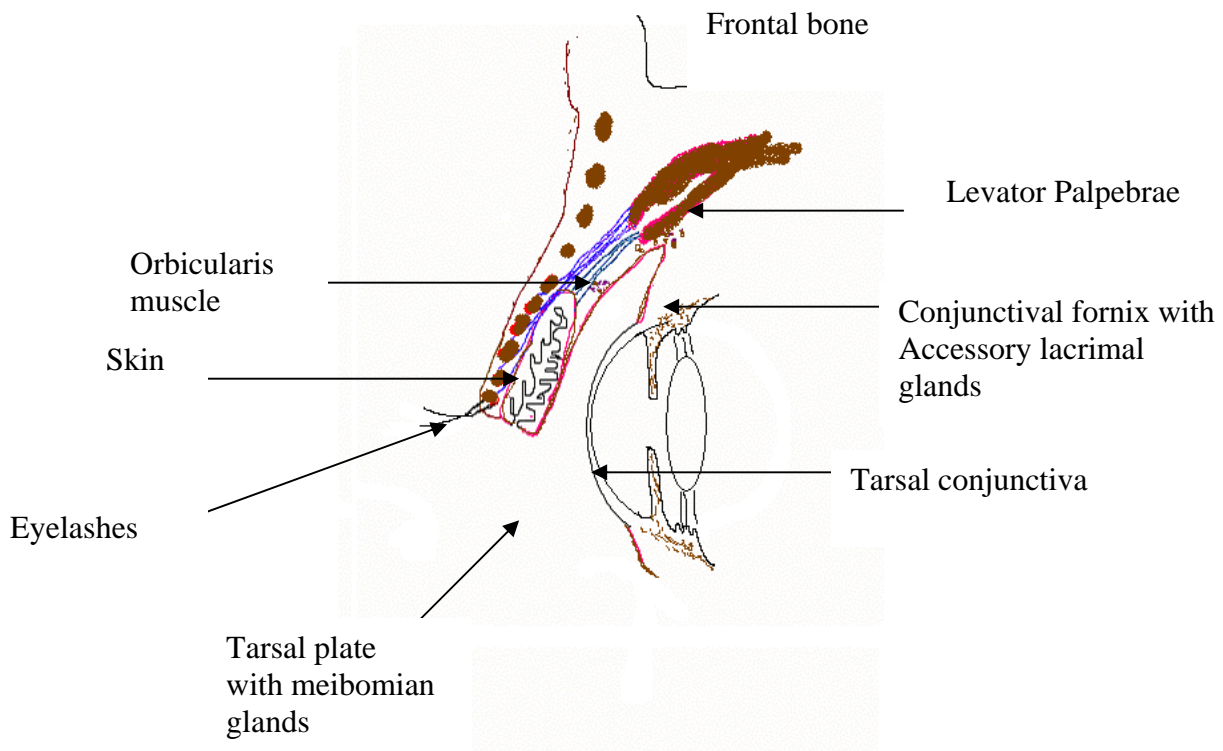


Fig 1.1. The structure of the eyelids and conjunctiva

C.LACRIMAL APPARATUS

- Consists of

- Lacrimal gland
- Punctum
- Canaliculi
- Nasolacrimal sac
- Nasolacrimal duct

Lacrimal apparatus produces and drain tears that forms component of tear film

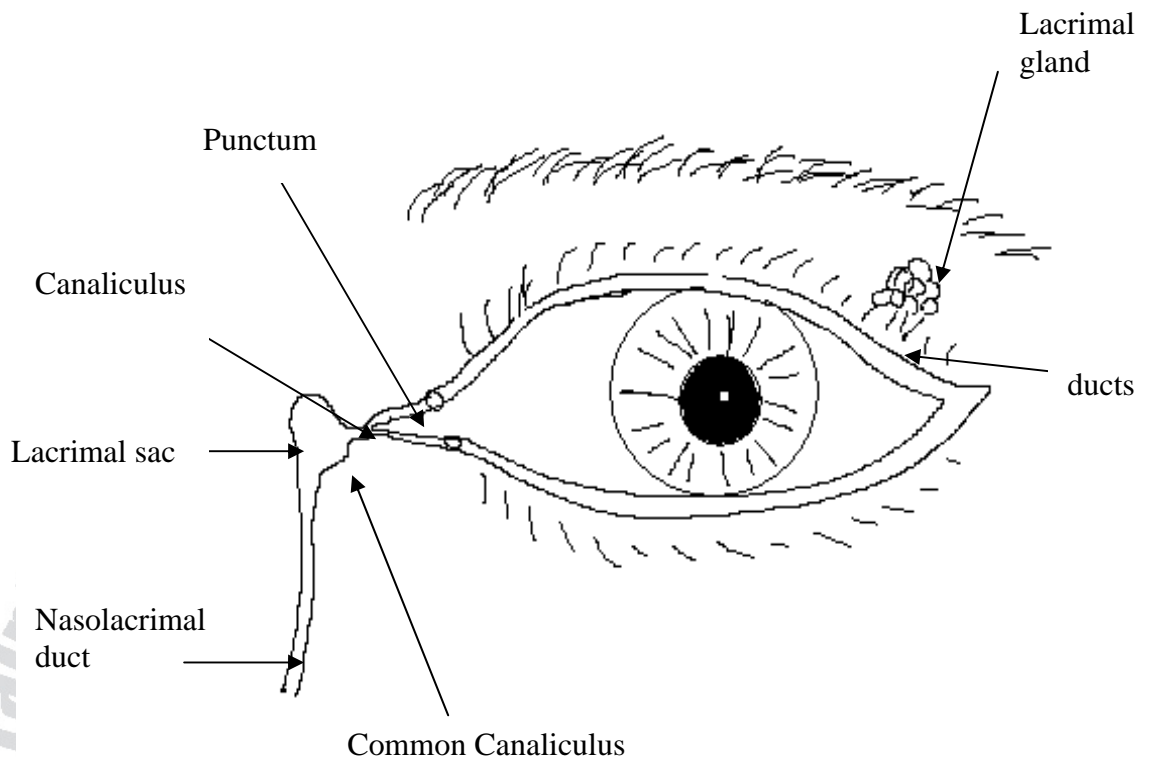


Fig 1.2. The Lacrimal apparatus.

-The tear forms a thin film of fluid on the surface of the conjunctiva and cornea, which is vital for the health, and transparency of the cornea.

- Outer part(Lipid layer)- oily secretion from meibomian and Zeis gland
- Middle part(Aqueous layer)-Water from Lacrimal gland and accessory lacrimal glands of Krause and Wolfring.
- Inner part(Mucin layer)-Mucus from goblet cells of the conjunctiva

Function of tear film.

- 1-provides moist environment for the surface epithelial cells of the conjunctiva and cornea
- 2- Along with the lids, it washes away debris
- 3- Transport metabolic products (oxygen, carbon dioxide) to and from the surface cells
- 4- Antimicrobial actions
- 5- Provides a smooth refracting surface over the cornea




Fig. 1.3. Components of tear film

D- ORBITAL BONES

The orbit is formed by seven bones and has four walls.

Wall of orbit-

Roof

Frontal bone and sphenoid bone

Floor

Zygomatic, maxillary and palatine bones

Medial

Ethmoid, frontal, Lacrimal and sphenoid bones

Lateral

- The strongest of all walls.

Zygomatic and sphenoid bone

1.2- THE GLOBE /EYE BALL/

The globe is a visual organ which weighs 7.5 gm and has an average diameter of 24mm.

- Has three coats

I- Outer coat/ fibrous/- sclera and cornea.

II- Middle layer/vascular/- iris, ciliary body, choroids

III- Inner layer/neural/- sensory retina and pigment epithelium.

- Has three ocular chambers

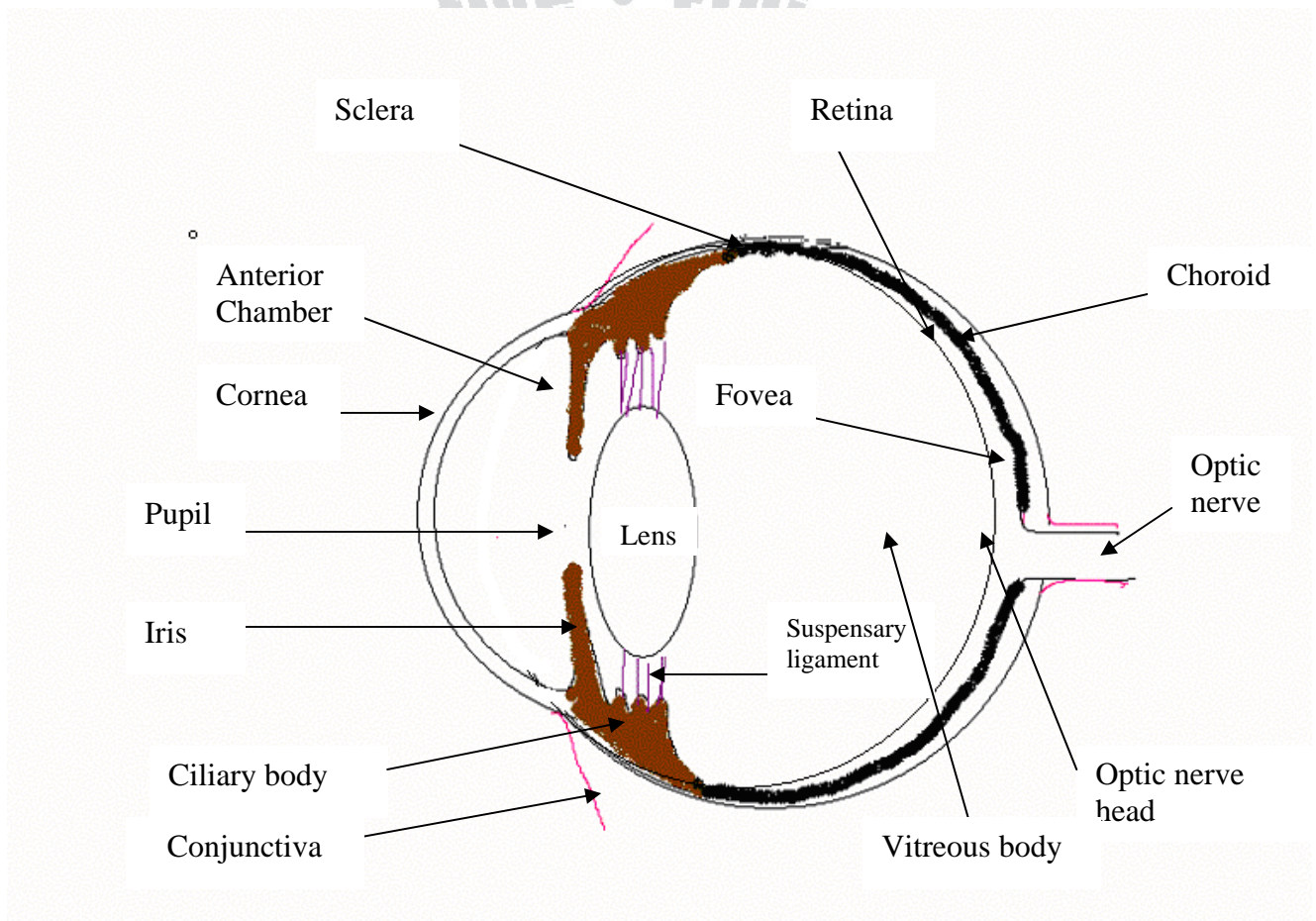
I- Anterior Chamber

II- Posterior Chamber

III- Vitreous Space

-Associated structures (Adnexa)

- Eye lids with all its parts, extra ocular muscles, Vessels, nerves, lacrimal apparatus, adipose and connective tissues.



1.4. The basic structure of the eyeball to show its three layers.

1.2-1 FORM AND FUNCTIONS OF THREE OCULAR COATS

A - THE OUTER COAT

I. Sclera

- Means tough.
- Is an opaque and thick coat made of collagen fibers.

- Is poorly vascularized but is sandwiched between the highly vascularized episclera and choroid.
- The metabolic requirements are met by diffusion.
- Constitutes the posterior 5/6th of the globe.
- important to protect and keep the shape of the globe

II. Cornea

- Is the main refractive media of the eye (75 % of refractory function of the eye).
- Avascular but obtains its metabolic needs from the vessels of limbus and aqueous fluid, and oxygen from atmosphere.
- Thickness varies from 0.5mm centrally to 1 mm peripherally.
- Has very rich sensory nerve supply from ophthalmic branch of trigeminal nerve.

It has three layers

a) **Surface epithelium**

.5 or 6 cells thick, of non keratinized stratified Squamous epithelium.

Continuous with conjunctival epithelium

Constantly changing or shedding.

b) **The inner stroma**

- Main bulk of cornea /accounts for 90% of corneal thickness
- Has two additional membranes

I- Bowman's membrane is special support of surface epithelium.

II- Descemet's membrane is tough support of endothelium.

c) **Inner surface (endothelium)**

- Single layer of very active cuboidal cells.
- Transfers fluid out of the stroma and keep the cornea dehydrated.
- can't regenerate but can expand to adjust damaged cell

B. THE MIDDLE LAYER

- Consists of the iris, ciliary body and choroid.
- They are continuous with one another and are collectively known as the uveal tract (uvea Latin word means grape).

1. Iris

- has central hole (pupil) through which light reaches the retina
- consists of a vascular stroma covered by mesothelium anteriorly and by two pigmented layers of epithelium posteriorly.
- It is continuous with the ciliary body
- has smooth (involuntary) muscle.
- It has two muscles
 - I) The sphincter pupillae
 - Located in the pupillary zone with breadth of 1mm
 - Innervated by parasympathetic fibers
 - Stimulation of the muscle causes constriction of the pupil (miosis)
 - II) The dilator pupillae
 - Extends radially from the ciliary body to the sphincter muscle.
 - Innervated by sympathetic fibers
 - Stimulation causes pupillary dilatation (mydriasis).

N.B the pupil is never at rest. Its size is subject to various factors like aging, illumination, sleep, change of gaze, emotional status.

2. Ciliary body

- Triangular structure that is situated between the iris anteriorly and choroids posteriorly.
- Has
 - I) ciliary process- site of aqueous fluid production.
 - ii) Ciliary muscle- important for accommodation- (When it contracts lens become more round in shape and the zonular ligament become loosen then increased focusing power to make clear near vision).

- Attached to the lens with suspensory ligament and helps to keep it in its position.

Circulation of aqueous fluid

Aqueous fluid is produced by ciliary process of ciliary body. It flows from the posterior Chamber along the pupillary opening to the anterior chamber. Finally it will be drained through the Canal of schlemm in the Trabecular meshwork to episcleral veins

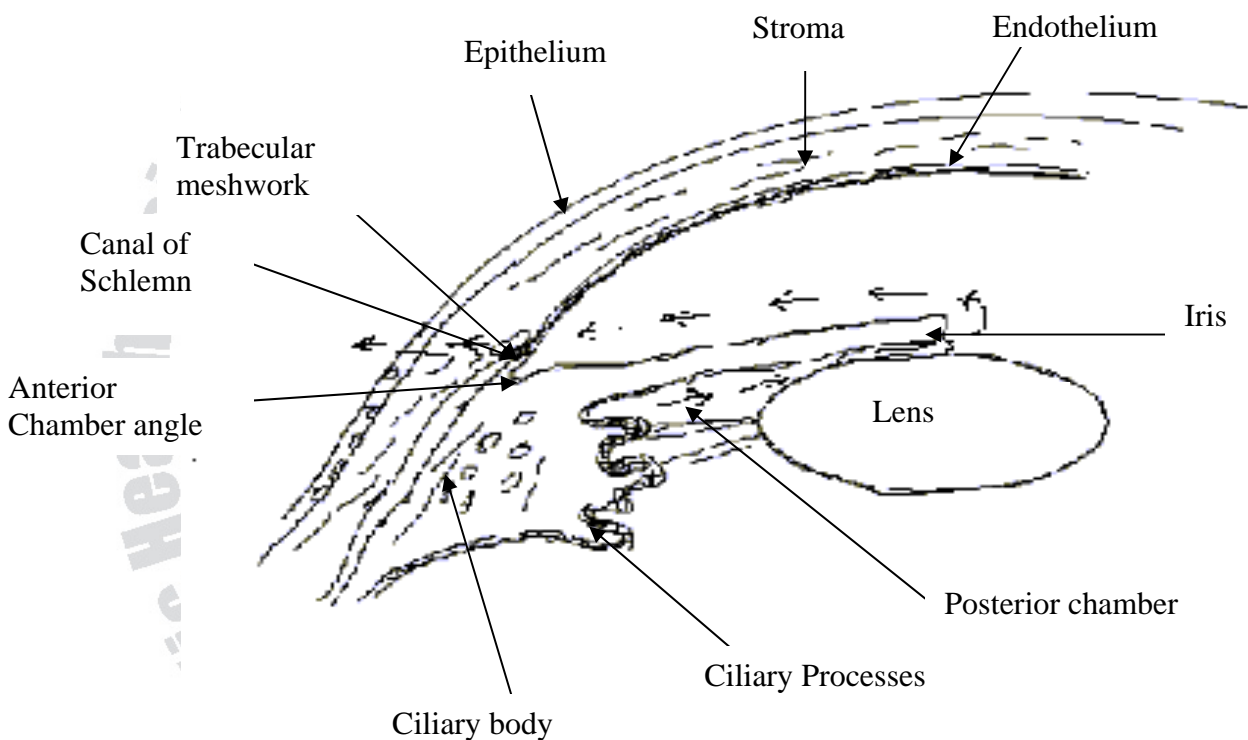


Fig.1.5 Enlarged view of the angle of the anterior chamber.

3. The Choroids

- It is network of blood vessels
- The arteries and veins are located externally while capillaries are found internally.
- Is responsible for the blood supply of the outer half of the retina.
- It has pigment cells that absorb light to prevent unwanted reflection.

C.THE INNER COAT- RETINA

- Thin, transparent, net like membrane with a high rate of oxygen metabolism.
- Consists of two kinds of photoreceptors.

Cones- color & bright light sensitive cells that are found toward the center.

Rods- sensitive to dim lights that are found peripherally.

These are antennae of visual system i.e. react with light and light energy is transformed into a visual perception.

Have two layers

I- Outer layer

- Next to choroid, single layer of fragment epithelial cell.
- Contains rods and cones.
- Avascular and gets its nutrition from choroid by diffusion.

II- The Inner Layer

- Consists of bipolar and ganglion cells as well as nerve fibers and synapses.
- Light passes through this to reach rod and cones.

- This produces electrical impulses when they are exposed to light. The electrical impulses produced by each rod or cone passes across synapses to the bipolar cell. Then the impulses are modified in various ways as they pass through the bipolar and ganglion cells. The nerve fibers from the ganglion cells travel in the nerve fibers layer on the surface of the retina to the optic disc and form the optic nerve.

Two important parts of the retina

1.Macula Lutea

- Point of sharpest vision and color vision
- About 1.5 mm in diameter and is located two disc diameter temporal to optic disc
- It appears darker than the rest of retina
- Yellows spot (fovea) is a depression at the centre of the macula and shines during ophthalmoscopy. (Foveal reflex).

The yellow color is due to the presence of carotenoid pigment (xanthophylls). This is used to protect the macular cones from the dazzle of incident light, which occurs even with maximal pupillary constriction.

- Visual acuity varies depending on the concentration of cone . Foveal vision is 1.0(20/20) as you move away from it V/A decreases.
- It is the center of visual axis.

2-Blind spot

- Is an area of complete blindness in the visual field.
- Anatomically it corresponds to optic nerve head, which is located nasally and measure 1.5 mm in diameter.
- At this point, there are no photoreceptors.

1.2.2. THE CHAMBERS OF THE GLOBE

A. Anterior chamber

- Delineated anteriorly by the posterior corneal surface and posteriorly by iris.
- Depth- 3-4 mm
- Volume of aqueous humor in the anterior chamber is about 0.25 ml
- Inflow and outflow are balanced so that the entire contents of anterior chamber are replaced every 10 hrs.

B. Posterior chamber

- Limited anteriorly and laterally by the posterior iris surface and ciliary body and posterior by lens & vitreous body

C. Vitreous space

- Filled with vitreous humor
- Transparent, roughly spherical and gelatinous structure occupying posterior 4/5 of the globe with volume of 4 ml.
- Consist of water (99 %), collagen, hyaluronic acid and soluble protein.
- Inert
- Function: - to act as intervening medium in the light pathway between the lens and retina and also gives the shape of the eye.

1.2.3. THE LENS

- Consist of closely packed transparent cells enclosed in a capsule.
- Has unique feature
 - Transparent
 - No blood or nerve supply.
 - Has higher protein content than other body tissues.
 - Continues to grow through out life, new in the top, old compressed to ward the centre.
 - The only solid structure inside the eye.
 - Has biconvex shape.
 - Epithelial cells are not shedding type
 - Has three anatomical parts: capsule, cortex, nucleus

Its nutrition is maintained by the metabolic exchange between itself and the aqueous humor.

1.3 BLOOD SUPPLY, INNERVATIONS AND LYMPHATIC DRAINAGE OF THE EYE

1.3.1 Blood supply of the eye

A- Arterial blood supply

The eye is supplied by anastomosing vessels from internal and external carotid arteries.

- * Retina - inner layer gets blood from central retinal artery, a branch of ophthalmic artery and enters the eye with optic nerve and divides on the optic disc into its branches.
- * Uvea - is supplied by ciliary circulation, from ophthalmic artery.
- * Eye lid gets its blood supply from facial and ophthalmic arteries.

B- Venous Drainage

Almost the entire blood from the anterior and posterior uvea drains through four vortex veins via superior and inferior orbital veins to cavernous sinus.

Eye lid drains through facial vein into cavernous sinus

1.3.2. Lymphatic drainage

There are no lymphatic vessels inside the globe. The lymphatic drainage of the medial eye lid is to sub mandibular lymph node and that of lateral one is to the superficial preauricular lymph nodes and then to deeper cervical lymph nodes.

1.3.3 Innervations of the eye

A- Motor

- Oculomotor (CN III) Innervate- medial rectus, superior rectus, inferior rectus, & inferior oblique.
- Trochlear (CN IV) nerve- innervates superior oblique
- Abducent (CN VI) nerve- innervates lateral rectus.
- Facial nerve (CN VII) - innervates orbicularis oculi muscle

B- Sensory nerve

- Ophthalmic branch of trigeminal nerve is the sensory nerve of the globe & adnexa and has three branches -frontal, lacrimal, nasociliary.
- Optic nerve (CNII) - responsible for vision.

C- Autonomic nerves

- I- Sympathetic nerve- supplies Muller's muscles and dilator pupillae.
- II- Parasympathetic comes via oculomotor and innervates the ciliary muscle and sphincter pupillae.

1.4 EXTRA OCULAR MUSCLES

- They are six, and their action is so complex.
- Control eye movement
- Form cone behind the eyeball

Table 1.1 Extra ocular muscles and their action (monocular action)

- Superior rectus	for upward movement of the eye
- Inferior oblique	inward and up ward movement of the eye
- Medial rectus	inward movement of the eye
- Lateral rectus	outward movement of the eye
- Inferior rectus	for downward movement of the eye
- Superior oblique	- inward and down ward movement of the of the eye

Exercise

1. What is unique character of skin in the eyelid?
2. What are the components of eyelid and their function?
3. Discuss about lacrimal apparatus, anatomical and physiological aspect.
4. List the middle layers of the eyeball with their function.
5. What is the difference between blind spot and fovea?
6. What are the unique features of the lens?
7. Discuss about the circulation of aqueous humor.

Reference

- 1- John sand ford – smith, **Eye disease in Hot Climate** c reed Educational and professional publishing LTD, 1997
- 2 - Kanski **clinical ophthalmology** c reed Educational and professional publishing LTD 1999
- 3 - Kenneth W.wright, **A text Book of ophthalmology** - E. Ahmed
- 4 - Albert and Jakoboiec **Principle and practice of ophthalmology**
- 5 - **Up to date** - (C) 2001 - www.up to date.com. (800) 998-6374.(781)237-4788
- 6 - D. Vaughan General ophthalmology

UNIT TWO

BASIC EXAMINATION OF THE EYE

- 2.1. HISTORY TAKING
- 2.2. TESTING VISION
- 2.3. EXAMINING THE EYE

Objective:

1. To give a clear idea about the approach to ophthalmic patients and specific examination techniques.
2. To familiarize the students with certain ophthalmic instruments.
3. At the end of the course the students are expected to know how to examine ophthalmic patients and use of certain ophthalmic instruments

2.1. HISTORY TAKING: -

History taking should follow this out line

1. Personal details
 - Name
 - Address
 - Age
 - Occupation
2. History of the present complaint
3. General health and any medication the patient may be taking
4. Past ophthalmic medical and surgical history
5. Family history

The main purpose of the history is to find out what exactly the patient is complaining. However it is always helpful to find out some background information about the patient e.g. age, sex, occupation, and literacy. Such information will indicate what vision the patient needs for work and for personal satisfaction.

In History taking one has to consider the following

- Particular environmental or occupational factors
- Patients diet, drinking and smoking habits
- General health of the patient like diabetes, hypertension & neurological disease affecting the eye.
- Previous eye disease, injuries or treatment
- Use of traditional medicine or uses of other treatment.
- Family history of similar complaint e.g. myopia and glaucoma.

Major symptom of eye disease given

- Disturbances of vision
- Discomfort or pain in the eye
- Eye discharge

A. Disturbances of vision

- The most common visual symptom
- Can be sudden or gradual
- Blurring or reduction of vision
- Dazzling/glare/ – difficulty of seeing in bright light, may be caused by opacities in the cornea or lens
- Diplopia/ double vision/
- Decreased peripheral vision – may be caused by various disorders in the retina, optic nerve or visual pathway pathology up to the visual cortex.
- Photophobia – is a fear of light
 - It is usually a sign of inflammatory eye disease, especially a corneal ulcer and uveitis.
- Distortion of shapes usually indicates a disorder of the retina around the macular.
- Haloes (rainbow) colored rings around the light e.g. Corneal edema, Glaucoma.

B. Discomfort or pain in the eye.

- Usually a symptom of inflammation of the eye or of the structure surrounding the eye.
- Discomfort, irritation or grittiness – conjunctival problems
- Pain – related to corneal disease, Glaucoma

Eyestrain and tiredness of the eyes are common complaint usually associated with extra ocular muscles abnormalities and refractive errors.

C. Eye discharge

- type (mucoid, purulent, watery)
- amount

2.2. TESTING THE VISION

- A. Visual acuity
- B. Visual field
- C. Color vision

A. Visual Acuity

- Test the visual acuity in each eye separately.
- Measured with a Snellen chart, showing letters, 'E' chart or pictures for patient who cannot read.
- Patient should sit at 6 meters
- Start with the right eye by closing the left eye with palm of the hand.
- Use commonly 'E' chart and ask the patient to show the direction of the 'E' (right, left, up or down) and then record the last line that the patient sees.
- Repeat for the left eye.
- The human finger is about the same size as the top letter on the chart, so counting fingers at 6 meters is about equal to 6/60 vision, and abbreviated as *CF*

- If vision is below 1/60, use the patient to detect motion of hand in front of the eye; 'hand motion' (*HM*)
- If the patient can't see *HM*, the final test is to shine a light into his eye
 - If he can perceive light – *LP*
 - If he can't perceive light – *NLP*
- Projection of the light from four quadrants of the eyes should be examined to test the peripheral retina and optic nerve function.
- Test for red and/or green color discrimination, macular function test
- Pin hole test – If V/A improves with this test, it usually indicates an error of refraction; But if not corrected, then loss of visual acuity is from other eye diseases.
- Interpretation of V/A

The WHO classification of Visual impairment and blindness

- | | | |
|---------|--------|----------------------------|
| ▪ 6/6 | -6/18 | : Normal |
| ▪ <6/18 | -6/60 | : Visual impairment |
| ▪ <6/60 | - 3/60 | : severe Visual impairment |
| ▪ <3/60 | - NPL | : blindness |

Blindness is defined as visual acuity of less than 3/60 in the better eye with the best possible correction.

B. Visual field

Visual field is that portion of one's surroundings that is visible at one time during central vision

Not a routine test in all patients

- Important to do in any patients with suspected glaucoma, diseases of the optic nerves in visual pathways, and certain retinal diseases

Confrontation test

- Simple and no need of special equipment
- Will detect serious visual field defects.
- Works by comparing the patient's visual field with the examiner's

Steps

- Sit facing the patient at one meter distance
- If the patient's left eye is being tested, he should cover his right eye and you should cover your left eye.
- Patient looks straight into your eye and you look straight into his to make sure he is fixing your eye.
- Then hold your fingers at an angle equidistant between you and the patient and ask him to say visible or not as your fingers move.
- If you can see them and the patient cannot, then he has a defect.
- Move in different quadrant
 - Do the same with the other eye.

Perimetry

- Difficult to test in children, old or non comprehending people.
- In all visual field test, each eye is tested separately
- The patient must fix his gaze on a target or spot in front of him.
- The examiner then sees at what angle objects come into the patients range of vision

A calibrated black screen / Bjerrum screen/

- Give a more accurate result

C. Color vision

- Done by using a chart called 'Ishihara chart'.
- Simple macular test is to ask the patient for red and green color perception

2.3. EXAMINATION OF THE EYE

- ❖ Nearly all parts of the eye are visible with an appropriate optical instrument.
- ❖ Anyone who cares for the patients should know how to examine the eye.
- ❖ Some of ophthalmic diagnostic instruments are very expensive, but a reasonable examination is possible with available simple

instruments. There are two important instrument for examination of the eye

1. To examine the front of the eye, this requires both a good light illumination with bright light, torch and magnifying lens(loupe).
2. To examine the back of the eye, need ophthalmoscope.

Normal eye

- Eye lids should open and close properly
- Eye lashes should grow forward and out ward
- white part of the eye should be white
- Cornea should be clear and transparent
- Pupil is black and reactive to light

During Examination of the Eye One Has to Comment the Following Things

1. Examination of the front aspect of the eye

Eye lids –

- ❖ In growing eye lash, misdirected
- ❖ Everted eyelid examinations; follicles, papillary reaction, foreign body, concretions
- ❖ Any mass, ulcer, discharge
 - Characterize it
- ❖ Opening and closing pattern and defect of eye lid
 - Lagophthalmos – eye lid that can't close
 - Ptosis – eye lid drooping

Nasolacrimal apparatus

- ❖ Punctum
- ❖ Mass, Ulcer or discharge over the Nasolacrimal apparatus

Conjunctiva

- Color
- Growth

- Bleeding
- Foreign body
- Spot - white foamy
- Follicles, papillae, scarring

Characterize each findings

Limbus

- Herbert's pit
- Ciliary /circumcorneal/ injection
- Arcus

Cornea

Color and transparency
Size
Ulcer, scar, infiltrates
Foreign body
Laceration, perforation
Blood vessels growth
Sensation to touch

Iris /pupil

- Color
 - Defect
 - Reaction to light
 - Relation with adjacent parts
 - Pupillary margin: shape, adhesion between lens , iris and cornea

Lens

- Transparency
- Position, subluxated or dislocated

Anterior chamber

- look for clarity
- Depth

2. Examining the fundus and using the ophthalmoscope.

Ophthalmoscope is a form of illumination, which allows the examiner to look down the same axis as the rays of light entering the patient's eye.

To see the fundus

- Ocular media must be healthy and transparent
- Dilate the pupil with mydriatic drops
- With the ophthalmoscope it appears 15 times larger than its actual size
- In myopic patient the magnification is greater, but in hypermetropic patient it is less.

How to use ophthalmoscope

- Hold closer both to the examiner's and to the patient's eye
- If the patient has spectacles, he has to put it off.
- If the examiner wears spectacles, he should keep it.

Steps

- A. For examination of the right eye, sit or stand at the patient's right side.
- B. Select " O" on the illuminated lens dial of the ophthalmoscope and start with small aperture.
- C. Take the ophthalmoscope in the right hand and hold it vertically in front of your own right eye with the light beam directed toward the patient and place your right index finger on the edge of the lens dial so that you will be able to change lenses easily if necessary.
- D. Dim room lights. Instruct the patient to look straight ahead at a distant object.

- E. Position the ophthalmoscope about 6 inches (15cm) in front and slightly to the right(25°) of the patient and direct the light beam into the pupil. A "reflex" should appear as you look through the pupil.
- F. Rest the left hand on the patient's forehead and hold the upper lid of the eye near the eyelashes with the thumb. While the patient holds his fixation on the specified object, keep the " reflex" in view and slowly move toward the patient. The optic disc should come into view when you are about 1and1/2 to 2 inches (3-5cm) from the patient. If it is not focused clearly, rotate lenses into the aperture with your index finger until the optic disc is clearly visible as possible. The hyperopic, or far-sighted, eye requires more" plus"(black numbers)sphere for clear focus; the myopic, or near-sighted, eye requires " minus"(red numbers) sphere for clear focus.
- G. Now examine the disc for clarity of outline, color, elevating and condition of the vessels. Follow each vessel as far to the periphery as you can. To locate the macula, focus on the disc, then move the light approximately 2 disc diameters temporally. You may also have the patient look at the light of the ophthalmoscope, which will automatically place the macula in full view. Examine for abnormalities in the macula area. The red-free filter facilitates viewing of the center of the macula, or the fovea.
- H. TO examine the extreme periphery instruct the patient to:
- a) look up for examination of the superior retina
 - b) look down for examination of the inferior retina
 - c) look temporally for examination of the temporal retina
 - d) look nasally for examination of the nasal retina.

This routine will reveal almost any abnormality that occurs in the fundus.

- I. To examine the left eye, repeat the procedure outlined above except that you hold the ophthalmoscope in the left hand, stand at the patient's left side and use your left eye. If you don't get a clear view it is usually for one or two reason
1. If the patient has a refractive error, try dialing up plus or minus lenses in the ophthalmoscope to bring the fundus into focus.

Especially in myopic patient. It is difficult to see the fundus clearly so use a strong minus lens in the ophthalmoscope.

2. If the patient has some opacity in the transparent part of the eye i.e. in the cornea, lens or vitreous, this can be detected with plus lens in the ophthalmoscope when the pupil is dilated.

Options of Examining a Young Child

1. Seat the baby on his mother's lap, so that her hands restrain his arms and steady his head
2. Wrap the baby in a sheet or blanket, with his head on the examiners lap, and continue what you are going to do
3. In very difficult cases, it may be necessary to apply a drop of local anesthetic, and use a speculum to hold open the eyelids. Use speculum cautiously as it will damage the cornea.

Intra ocular pressure

- Should be measured in any patient with suspected glaucoma.
- Ideally it should be part of routine eye examination in any one over 40 years of age.
- Measured by tonometry –
- There are three methods of assessing IOP
 - Digital palpation
 - Steps
 - Order your patient to look down
 - Place two fingers on the upper eye lid and depressing slowly
 - Assess the consistency of the globe (whether it is firm or hard) and compare with the fellow eye.
 - Schiøtz tonometry – cheap & commonly used
 - Applanation tonometry

Exercise:

1. What are the major complaints of a patient with eye disease?
2. Discuss about different visual tests.
3. Define blindness.
4. Describe the features of a normal eye.
5. What are the instruments used in the examination of the fundus of the eye?

1. Write down methods used in the measurement of IOP.

Reference

- 1- John sand ford – smith, **Eye disease in Hot Climate** c reed Educational and professional publishing LTD, 1997
- 2- Frith Hollwich, Ophthalmology
- 3- J. kanski **clinical ophthalmology** creed Educational and professional publishing LTD 1999
- 4- Kenneth W.wright ,**A Text Book of Ophthalmology** - E. Ahmed
- 5- Albert and Jakoboiec **Principle and practice of ophthalmology**
- 6- **Up to date** - (C) 2001 - www.up to date.com.(800) 998-6374.(781)237-4788
- 7- A manual for beginner of ophthalmology resident

UNIT THREE

EXTERNAL EYE DISEASES

3.1 DISEASES OF THE EYE LIDS

3.2 DISEASES OF THE LACRIMAL APPARATUS

3.3 ORBITAL INFECTION

Objective:

1. To give a basic knowledge on external eye diseases.
2. To give also basic concepts on how to diagnose and treat external eye diseases.
3. At the end of the course the students are expected to have adequate knowledge about eyelid and lacrimal apparatus disease; the diagnosis and management of such diseases.

3.1 DISEASES OF THE EYE LIDS

A. Internal Hordeolum

- a small abscess collection in the Meibomian glands
- Caused by staphylococcus

Symptoms pain, redness, swelling within eye lid

Signs tender, inflamed mass within the eye lid.

Treatment

- _ Hot compress
- _ Topical antibiotics
- _ If the above treatment fails, referral for
 - . Incision and curettage under local anesthesia

B. External Hordeolum /stye/

- An acute staphylococcal infection of a lash follicle and its associated gland of zeis or moll.

Symptom

- Pain, redness, lid margin swelling of short duration

Signs

- Tender inflamed mass in the lid margin which points anteriorly through the skin
- More than one lesion may be present and occasionally minute abscesses may involve the entire lid margin
- In severe cases a mild preseptal cellulitis may be present

Treatment

- Warm compression
- Topical antibiotic - Chloramphenicol eye ointment.
- Systemic antibiotic – cloxacillin 50mg/kg divided in four doses for 7 days if secondary eye lid cellulitis develops.
- Epilation of the eyelash associated with the infected follicle may enhance drainage of focus.
- If the above management fails and if there is an abscess, referral for surgical drainage.

C. Chalazion

- A chronic lipogranulomatous inflammatory lesion caused by blockage of meibomian gland orifices and stagnation of sebaceous secretion
- Patient with acne rosacea or seborrheic dermatitis are at increased risk of Chalazion formation which may be multiple or recurrent.

Symptom

- Painless nodule within the eye lid

Sign

- Non tender, firm, roundish mass within the eye lid.

Treatment

- Hot compression
- Referral for surgical incision and curettage

D. Molluscum contagiosum

- Uncommon skin infection caused by a poxvirus
- It is common in children and immunocompromized patient.
- In immunocompromized patient, it is multiple, large size, bilateral, recurrent and resistant to treatment.

Symptom – painless, raised, skin lesion.

Sign

- Single or multiple
- Pale, waxy
- Umblicated nodules
- If the nodule is located on the lid margin it may give rise to ipsilateral chronic follicular conjunctivitis and occasionally a superficial keratitis

Treatment

- Expression
- Shaving and excision
- Destruction of the lesion by cauterization, cryotherapy

E. Blepharitis

- a general term for inflammation of the eyelid
- Can be associated with conjunctivitis

There are two main types of blepharitis

1. Staphylococcal – blepharitis

- Caused by Staph. aureus
- Is ulcerative in type with redness of lid margins with scales and easily pluck able lashes

2. Seborrheic blepharitis

- Is associated with seborrhea of the scalp, brows and ears
- Is non –ulcerative
- The scales are greasy with less marked redness of the lid margin

A patient may present with a mixed type of Blepharitis(see color plate -12)

Both types of patients could present with:-

Symptoms

- Irritation

- Burning
- Itching of the lid margins

Signs

- Scales on lid margin
- Eye lid margin ulceration and redness

Treatment

- Lid hygiene
- Topical antibiotics (erythromycin or Chloramphenicol eye drops QID) – for infectious
- Systemic antibiotics-doxycycline 50 to 100 mg/day for four weeks for infectious
- Topical steroid (terracortril eye suspension once – twice a day) for seborrheic

ABNORMALITY IN THE FUNCTION AND POSITION OF THE EYELIDS

A. Ectropion

- Means eversion of eyelid.

Treatment

- Referral for surgical correction.

B. Entropion

- Means the eyelids turn in wards then the eyelashes rub and damage the globe

Treatment

- Referral for surgical correction

C. Ptosis

Ptosis means drooping of the upper eye lid due to Levator muscle weakness. It can cause amblyopia if it is unilateral

Treatment

- Referral for surgical correction

3.2 DISEASES OF THE LACRIMAL APPARATUS

Dacryocystitis

Definition: is an inflammation of the lacrimal sac that occurs primarily because of Nasolacrimal duct obstruction. Chronic tear stasis and retention leads to secondary bacterial infection.

Etiology

Staphylococcus, Pneumococcus, Streptococcus .etc

Classification: Clinically classified as acute and chronic dacryocystitis

Acute dacryocystitis

Symptoms

- Painful, swollen mass below the medial side of the eye
- Conjunctival injection, tearing

Signs

- Tender mass on the medial side of the eye.
- Pressure on the sac will often fail to result in regurgitation of mucopurulent material.

Treatment

- Hot compression
- Systemic antibiotic
- Incision and abscess drainage may be required

Complication

- Preseptal cellulitis
- Orbital cellulitis

Chronic dacryocystitis

Symptoms

- Tearing
- Swelling over the medial aspect of the eye
- Mucoïd or purulent discharge with pressure on the lacrimal sac area.

Signs

- Non tender mass on medial aspect of the eye
- Decompressing digitally over the mass drain mucoid or purulent discharge through the punctum.

Treatment

- Referral for surgery (dacryocystorhinostomy)

3.3 ORBITAL INFECTION

Etiology

- H. influenza, S. aureus, S. pneumoniae etc.

Predisposing factor:

- trauma, stye, dacryocystitis etc.

Preseptal cellulitis

Definition: it is infection of the tissues anterior to the orbital septum

Symptom

- No visual reduction
- Mild periorbital pain
- Localized eyelid redness and swelling

Sign

- V/A is normal
- Tender and hot eyelid
- Ocular motility is normal

Treatment

- Ciprofloxacin 500mg po bid for seven days. If no improvement within 48hrs, it needs early referral.

Orbital cellulitis

An infection of orbital tissue posterior to the orbital septum.

Symptom

- Pain
- Proptosis
- Fever
- Limited ocular movement
- Visual reduction

Sign

- V/A is reduced
- Tender eye
- Reduced to absent ocular motility

Treatment

It is an ophthalmic emergency that needs admission; intravenous antibiotics and close follow up. So early referral to ophthalmic center is highly recommended.

Complication

If it is left untreated, it is vision and life threatening.

- Loss of vision
- Meningitis
- Brain abscess
- Cavernous sinus thrombosis

Exercise:

1. Discuss the difference between internal and external Hordeolum.
2. What is the difference between Chalazion and molluscum contagiosum?
3. Define the following terms
 - Ectropion
 - Entropion
 - Ptosis
4. How do you differentiate preseptal cellulitis from orbital cellulitis?

Reference

- 1- John sand ford – smith, **Eye disease in Hot Climate** c reed Educational and professional publishing LTD, 1997
- 2 - J. kanski **Clinical Ophthalmology** c reed Educational and professional publishing LTD 1999
- 3 - Kenneth W.wright, **A Text Book Of Ophthalmology** - E. Ahmed
- 4 - Albert and Jacoboiec **Principle And Practice Of Ophthalmology**
- 5 - **Up to date** - (C) 2001 - www.up to date.com.(800) 998-6374.(781)237-4788

UNIT FOUR

DIFFERENTIAL DIAGNOSIS OF RED EYE

Objective:

1. To give an idea on the commonest causes of red eye.
2. They will also be alert on the differential diagnoses ranging from self limiting to sight threatening cause of red eye.
3. They will be given a clear description on how to approach patients with red eye and what to do at their level.
4. At the end of the course, students are expected to differentiate self limiting condition from sight threatening conditions; and to act early.

THE RED EYE

The differential diagnoses of red eye are protean ranging from trivial conditions like sleeplessness and fatigue to life threatening conditions as cavernous sinus thrombosis and carotid cavernous fistula.

Clinical simple and conventional way of categorizing causes of red eye

1. Painless red eye

- i. Conjunctivitis
- ii. Pterygium and others

2. Painful red eye

- i. Keratitis and corneal ulcer
- ii. Iridocyclitis
- iii. Acute angle closure glaucoma
- iv. Episcleritis and Scleritis

PAINLESS RED EYE

Causes of painless red eye are mostly self limiting .If they are neglected and mismanaged they will complicate to the extent of sight threatening condition.

Appropriate evaluation and management is recommended. Those patients who will not have improvement in less than 48 hrs need referral to a better center for better management.

Conjunctivitis

Def. Conjunctivitis is a general term for any inflammation of the conjunctiva.

Epidemiology

The prevalence of each is different in pediatric and adult population. The vast majority of pediatric cases are bacteria, while in adult's bacterial and viral causes are equally common.

Bacterial conjunctivitis

- Commonly caused by staphylococcus aureus, streptococcus pneumonia, Hemophilic influenza, and moraxella catarrhalis
- S. aureus is common in adults
- Highly contagious from secretions or with contaminated objects and surfaces.

Symptoms:-

- Patients typically complain of redness and discharge in one eye; although it can also be bilateral.
- The affected eye often is “stuck shut” in the morning
- Purulent discharge continues through out the day.
- The discharge is thick; it may be yellow, white or green.
- No real pain as the conjunctiva has few sensory nerve supplies but complain of irritation, itching and discomfort
- Vision is almost always normal.

Sign: -

- On examination, patients will typically have purulent discharge at the lid margins and in the corners of the eye. More purulent discharge appears within minutes of wiping the lids
- Red eye – due to dilatation of superficial blood vessels as apart of inflammation

- Edema of the conjunctiva (chemosis) and eyelids swelling
- Cornea is mostly clear; but if it is involved, there will be different degree of corneal opacity it is common special in untreated and delayed patients

(see color plate14)

Diagnosis

- Mostly clinical
- Gram stains

Course

- It lasts for 1 - 2 weeks and then it usually resolves spontaneously.

Treatment

- Chloramphenicol eye drop or ointment QID
- Ciprofloxacin eye drop QID
- If the above drugs are not available, one can use tetracycline eye ointment BID
- Evaluate the patient after 48 hrs and if no improvement, refer to ophthalmic center for better evaluation

N.B. Don't use steroid or steroid containing antibiotic as they will reduce local immunity and encourage micro organism to multiply

Viral conjunctivitis

- It is highly contagious, spread by direct contact with the patient and his or her secretions or with contaminated objects & surface
- Patient usually presents with watering, photophobia, irritation and mostly associated with upper respiratory tract infection

Treatment

- Self limiting
- Prophylactic topical antibiotics, Chloramphenicol TID
- Never use steroid or steroid containing antibiotics.

Allergic conjunctivitis

- Is caused by air borne allergy contacting the eye.
- With specific IgE, causes local mast cell degranulation and the release of chemical mediators including histamines, eosinophil chemo tactic factors and platelets activating factors.

Symptoms

- _ Red eye
- _ Severe and persistent **itching of both eyes**
- _ Mucoïd eye discharge
- _ No visual reduction

Signs

- _ V/A is normal
- _ papillary reaction to hypertrophy on tarsal conjunctiva

Treatment

- _ Cold compress
- _ Vasoconstrictor-antihistamine like cromolyn sodium
- _ Topical steroid -Terracortril eye suspension

Neonatal Conjunctivitis (Ophthalmia Neonatorum)

Defn: is conjunctivitis in a newborn (in the first 28 days of life)

Etiology Gonococcus and Chlamydia are the commonest cause of which gonococcal is most serious

Symptoms - profuse thin to thick purulent eye discharge

Sign - purulent eye discharge, eye lids are swollen
- If cornea is involved, ulcer, scarring, lately cornea will shrink.

Treatment

- It is sight threatening condition that needs systemic antibiotic and close follow up in better ophthalmic center
- Start with tetracycline eye ointment 3-4 times a day
- Urgent referral to ophthalmic center for further evaluation and management

Prevention

- The eye lids should be cleaned with saline swabs as soon as the head was born and before the infant's eyes opened.
- Then apply TTC eye ointment
- Should be applied routinely whenever there is a risk that the mother had these infection during pregnancy.

Pterygium

- Fleshy growth of the conjunctiva that encroaches the cornea and cover cornea (Pterygium means wing)
- It usually starts nasally, but occasionally temporally in the 3 o'clock or 9 o'clock.
- More common in dry, hot and dusty environment
- Patient complains slight cosmetic blemish, irritation of the eye
- If it grows into the pupil, it will cause blurring of vision to blindness (see color plate 1)

Treatment

- Protection from sun with eye glass or hat
- If irritated, topical steroid-Terracotril eye suspension BID
- Extensive crossing the limbus, it needs referral for surgical excision

Painful Red Eye

Those causes of painful red eye are so severe and sight threatening conditions. The diagnosis of such diseases need experienced ophthalmic worker, appropriate instruments and especial diagnostic tests and procedures. They should be evaluated by the ophthalmologist. Their visual out come highly depends on the time interval between onset of the disease and initiation of treatment and subsequent close follow up. So early referral to best center may salvage their vision.

Keratitis and corneal ulcer

The cornea is exposed to the atmosphere, and so often suffers from injury, inflammation or infection.

Common terms used in corneal disease.

- **Keratitis** -is the general word for any type of corneal inflammation.
- **Corneal ulcer**-is loss of some of corneal epithelium and inflammation in surrounding cornea.
- **Corneal scar** is white and opaque cornea, which is the final result of any serious inflammation.

Etiology - Virus, bacteria, fungi.

Symptoms

- Pain - sharp, and severe.
- Blurred vision - because the ulcer makes the corneal surface irregular and less transparent.
- Photophobia
- Red eye

Signs

- red eye -circumcorneal injection
- cornea -grayish to whitish infiltrate, hazy with loss of clarity and opacity of different degree(see color plate15)

Treatment

- Start with gentamycin or ciprofloxacin eye drop frequently
- For proper diagnosis, it needs slit lamp examination and culture. So early referral to ophthalmic center is recommended.

Iridocyclitis

Definition: inflammation of the iris and ciliary body.

Classification:

Etiology

- Associated with systemic diseases
- Infection
- Mostly idiopathic

Duration

- . Acute duration less than six weeks
- . Chronic duration above six weeks

Symptoms

- Painful red eye.
- Photophobia
- Reduction of vision

Sign

- V/A may be reduced
- Cornea is relatively clear
- Circum corneal injection
- Miosis (small pupil), may be irregular
- Anterior chamber may be hazy or loss of clarity (see color plate 10)

Treatment

- Start with topical steroids
E.g.-Dexamethasone eye drop _QID
- Atropine eye drop 1% BID to prevent adhesion and to reduce pain
- Refer as soon as possible to ophthalmic center

ACUTE ANGLE CLOSURE GLAUCOMA

Definition: - it is an elevation of IOP as a result of obstruction of aqueous outflow.

Symptoms

- Painful red eye
- Sudden reduction of vision
- Rapid progressive visual impairment.

- Periocular pain
- Nausea and vomiting, ipsilateral headache
- Rain –bow (haloes) vision around light

Signs

- V/A is decreased
- Firm to hard eyeball on digital palpation
- Circum corneal injection
- Cornea is hazy or loss of its clarity
- Anterior chamber will be shallow
- Pupil is mid dilated, sluggish and fixed
- Difficult to evaluate the fundus due to cornea edema.

Treatment

- Timolol eye drop 0.25% every 30 minutes
 - Acetazolamide (Diamox) 500mg PO stat and then 250 mg po QID
- With the above treatment, urgent referral to ophthalmic center

Episcleritis

Inflammation of the episclera below the conjunctiva.

- Ocular redness without irritation or pain and the redness typically persists for 24 to 72 hours then resolves spontaneously
- May be localized or diffuse

Treatment

- not sight threatening
- self limiting process
- topical vasoconstricting agent may reduce redness

Scleritis

- Inflammation of the sclera.

Symptoms

- Painful disorder-typically a constant severe boring pain that worsens at night or in the early morning hours and radiates to the face and

periorbital region. Pain is severe enough to limit activity and often to prevent sleep.

- Watering, redness, and photophobia
- Highly associated with systemic disease like rheumatoid arthritis, SLE, etc

Signs

- Sclera edema
- Tenderness

Treatment – Early referral for better management.

Table 4.1. Summary of differential diagnosis of the red eye

symptom	conjunctivitis	Corneal lesions, abrasion, FB, abrasion etc	Acute iritis	Acute angle closure glaucoma	Episcleritis/ scleritis
pain	discomfort	Pain, photophobia	Pain, photophobia	Severe pain	Aching pain localized tenderness
discharge	Muco-purulent	watery	watery	Slightly watery	Slightly watery
vision	Never impaired	May be impaired	impaired	Severely impaired	normal
hyperemia	generalized	Ciliary/ localized nearest to lesion	ciliary	ciliary	Near affected area
cornea	normal	Alteration of surface reflection and /or opacity	normal	Steamy-loss of luster	normal
pupil	normal	May be irregular or miotic	Small and /or irregular	Dilated and non reactive	normal
IOP/ tension	Normal	normal	May be raised	raised	normal

Exercise:

1. Write the clinical features and the management of bacterial conjunctivitis?
2. What are the commonest causes of neonatal conjunctivitis?
3. How can you prevent neonatal conjunctivitis?
4. What are the clinical features of a patient with iridocyclitis?
5. How are you going to manage a patient with iridocyclitis?
6. What are the commonest complaints of a patient with Keratitis of any sort?
7. What is the difference between Episcleritis and Scleritis? Discuss it.

Reference

1. John sand ford – smith, **Eye Disease In Hot Climate** c reed Educational and professional publishing LTD ,1997
2. Frith Hollwich, Ophthalmology
3. J. kanski **Clinical Ophthalmology** c reed Educational and professional publishing LTD 1999
4. Kenneth W.wright ,**A Text Book Of Ophthalmology** c Williams and Wilkins 1997
5. Albert and Jakoboiec **Principle and practice of ophthalmology**
6. **Up to date** - (C) 2001 - www.up to date.com.(800) 998-6374.(781)237-4788

UNIT FIVE

COMMUNITY OPHTHALMOLOGY

Objective

1. To give a general over view on the burden of blindness on global and country levels
2. To introduce the component, strategies and plans of vision2020.
3. To give a clear idea on the disease that have been launched by vision 2020 to control disease
4. At the end of the course, the students are expected to have adequate knowledge on the preventable cause of blindness and to act on these by managing at local level and referring early which are beyond their scope

INTRODUCTION

Blindness is defined as visual acuity of less than 3/60 in the better eye with the best possible correction

Epidemiology

World blindness

- Every 5 seconds one person in our world goes blind and a child goes blind every minute.
- An estimated 45 million people world wide are blind
- Every year, an additional 1-2 million persons go blind
- Around 80% of blindness is treatable and preventable
- A majority of the blind live in the poorest section of the developing world
- Without proper interventions the number of blind will increase to 75 million by 2020
- Causes of world wide blindness

- 1.Cataract _ 19.34 million
- 2.Trachoma – 6 million
- 3.Glaucoma _2 million

In Ethiopia

- an estimated 1.05 million blind people with the prevalence of 1.5%
- Causes of Blindness in Ethiopia
 - 1.Cataract(40%)
 - 2.Trachoma(30%)
 - 3.Measles/Vitamin A deficiency(4%)
 - 4.Glaucoma and others(26%)

Vision 2020

WHO and International Agency for the Prevention of Blindness have launched the plan called "vision 2020 the right to sight". 20/20 represents normal visual acuity recorded by the Snellen's method and measured in feet equivalent to 6/6 in meters. The hope is that by the year 2020 most of the avoidable blindness in the world should be eliminated, so that everyone in the world except those with untreatable and unavoidable disease should have a visual acuity of 20/20 by the year 2020.

The three main components (priorities) of Vision 2020 are

- 1-human resources development
- 2- Infrastructure and appropriate technology
- 3- Disease control (cataract, trachoma, onchocerciasis, childhood blindness, refractive error glaucoma and low vision).

1. CATARACT

Definition: It is lens opacity that causes visual impairment or blindness.

The word cataract is derived from Latin "catarracta" which means "water fall".

Epidemiology

- Around 19.34 million people are bilaterally blind (less than 3/60 in the better eye) from age related cataract. This represents 43% of all blindness.
- The number of blind people in the world and the proportion due to cataract is increasing due to:
 - Population growth
 - Increasing longevity.

The result of these two factors means that the population aged over 60 years will double during the next 20 yrs from approximately 400 million now, to around 800 million in 2020. This increase in the elderly population will result in a greater number of the people with visual loss and blindness from cataract that will need eye services. A figure of 1000 new blind people from cataract per million populations per year is used for planning purpose in developing countries.

Risk factors

- . Aging
- . Trauma
- . Ultraviolet exposure
- . DM

Classification

Anatomically

- Cortical cataract
- Nuclear cataract
- Posterior sub capsular cataract

Etiologically

- Age related / senile/
- Congenital cataract
- Traumatic cataract
- Metabolic cataract

Clinically

- Immature cataract is when there is area of clear lens part in between opacities; vision better than 3/60, still allows view of posterior pole (positive red reflex).

- Mature cataract is when the whole cortical lens is opaque obscuring the part of the lens, and vision worsen than 3/60.

Progress of the disease

Some patient develops mature cataract only in a few months after a sign of opacity in the lens, others with early opacity may persist in the lens for many years without obvious progress at all. However if opacity has formed it doesn't normally disappear spontaneously

Symptoms

- Progressive painless reduction of vision
- Dazzling/glare/ in nuclear cataract, in bright light the pupil constricts and vision deteriorates; become well in dim light.

Signs

- Reduced V/A
- Whitish opacity seen through the pupil(see color plate3)

Complication of unoperated cataract

- ❖ Dislocation or subluxation of lens
- ❖ Glaucoma
- ❖ Uveitis

Operable cataract eyes

The term is used to define a cataract where the patient and the surgeon agree to proceed with cataract surgery.

Treatment

Surgery-cataract extraction with intra ocular lens implantation.

Exercise:

1. What are the suggested risk factors for the development of cataract?
2. What is the complication of untreated cataract?
3. Discuss about the sign and symptom of cataract.
4. Discuss about different classification of cataract.



2. TRACHOMA

Definitions

Trachoma is a chronic infectious keratoconjunctivitis caused by *Chlamydia trachomatis*.

It is a Greek word meaning 'rough' which describes the surface appearance of the conjunctiva.

Epidemiology

- Very common disease, particularly in developing countries.
- Affects about 600 million people
- About 150 million people suffer from active trachoma
- Operable trichiasis and entropion in 11 million people
- 6 million of whom have gone blind due to the disease.
- The second largest cause of blindness in the world, after cataract.
- Leading cause of preventable blindness

How does the disease develop?

Trachoma tends to be found in dry rural areas, where lack of water and bad living conditions may facilitate the spread of the disease.

In communities where trachoma is common, infection starts in early childhood. The first signs can be found in children of less than one year old. Trachomatous inflammation becomes increasingly intense in children up to the age of six to eight years. Scars on the inside of the eye lids, caused by trachoma, can be found in children from the age of four years. Scarring is increasingly common in older children, but the serious complication of intumed eye lashes and corneal scarring do not usually appear before adult age. Thus, blindness due to trachoma is most common in adults.

Trachoma in the community

The severity of trachoma can vary from one community to another because of differences in the ease of spread of infection. Repeated

infections with *C. trachomatis*, or other causes of conjunctivitis, increase the intensity of inflammation, which leads to more scarring and blindness. Children are the main reservoir of Trachomatous infection, as they are commonly and heavily infected. Compared to men, women tend to have more severe trachoma, including intumed eyelashes and blindness, probably re infected by children for whom they care.

Risk factors

- Poverty
- Poor hygiene at individual, family or community level
- Lack of water supply
- Age and sex; common in children and women
- Environmental factors 4 Ds (Dust, Dry, Dirty, Discharge)

Transmission of trachoma

- Flies (*Musca Serbens*) eye to fly to eye
- Fomite eye to clothing to eye
- Finger eye to finger to eye

Common symptoms

- varies from a mild condition with hardly any symptoms at all, to a severe and blinding disease
- slightly mucopurulent discharge
- tearing
- foreign body sensation
- in severe cases, eyelid edema ,pain, red eye and photophobia

Sign

- Follicle (whitish spots beneath the conjunctiva)
- Edematous and thickened tarsal conjunctiva
- Upper tarsal conjunctival scaring
- Pannus- vascular growth into the cornea
- Herbert's pit- irregular upper limbus
- Trichiasis (misdirected eyelash with or without entropion)
- Corneal opacity (*see color plate from 4-9*)

Simplified WHO Grading of Trachoma

1- Active trachoma with follicles/TF/

- . Must be at least five follicles in the upper tarsal plate
- . Blood vessels of the conjunctiva are visible

2- Active trachoma intense/TI/

- . Edematous and thickened tarsal conjunctiva obscuring > 50% of blood vessels

3- Trachomatous scarring/TS/

- . White scar in the upper tarsal plate

4- Trachomatous Trichiasis/TT/

- . Evidence of one or more eye lash rubbing or touching the eye ball.
- . History of eye lashes Epilation.

5- corneal opacity/CO/

- . Central and sufficiently dense to obscure the part of pupil

Aims of simplified trachoma grading

1. To facilitate all health workers the recognition of the signs of trachoma and its complications
2. To enable health workers to assist in undertaking simple surveys to identify communities in need of measures to control blindness from trachoma.
3. To allow for easy evaluation, by health workers, of results of trachoma control efforts in identified communities.

Other terms, commonly used in older classification of trachoma, can be related to the present scheme.

Active Trachoma this implies the presences of ongoing Trachomatous inflammation, corresponding to TF, with or without TI “Cicatricial”, “healed” or “inactive” Trachoma Signs of Trachomatous inflammation are not visible, but scarring (TS with or without TT) is present.

Key measures for assessing the importance of trachoma in the community

1. The proportion of Trachomatous inflammation (TF, 20% or more with, or without TI) amongst children less than 10 years; this demonstrates how wide spread the infection is in the community
2. The proportion of intense Trachomatous inflammation (TI, 5% or more) in children less than 10 years; this demonstrates how severe the disease is in the community
3. The proportion of conjunctival scarring (TS); this demonstrates how common trachoma was in the past
4. The number of people with Trichiasis (1% or more); this indicates the immediate need to provide surgical services for lid correction
5. The proportion of people with corneal opacity (corneal blindness more than 0.1%); this demonstrates the impact of trachoma in the community in terms of visual loss.

Management of trachoma

Table 5.1 strategies for treatment of trachoma

Proportion of children (1-10) with trachoma	Basic treatment	Additional treatment
TF: 20% or more or TI: 5% or more	Mass topical treatment	Selective systemic antibiotic treatment of severe cases
TF: 5% to 20%	Mass or individual /family topical antibiotic treatment	As above
TF: less than 5%	Individual topical antibiotic treatment	Not indicated

Mass treatment (all members of all families in the community)

Tetracycline 1% eye ointment, either twice per day for six weeks or as intermittent treatment with ointment twice a day for five consecutive days per month, or a once daily application for 10 consecutive days, each month for at least six consecutive months per year.

Family treatment

Identify and treat families where there are one or more members with TF or TI; treat the whole family in accordance with one of the topical antibiotic regimens for mass treatment, as above.

Selective systemic antibiotics

- A. Doxycycline 100mg po/d for 21 days, don't give for children below 7 years, pregnant and lactating mother
 - B. Tetracycline 250 mg PO QID for 21 days, don't give children below 7 years, pregnant and lactating mother
 - C. Erythromycin 250mg QID for three weeks
 - D. Azithromycin 20 mg/kg PO single dose- don't give to pregnant lady and those less than six months of age. Maximum dose one gm and may require repeat dose after six months.
- TS - No treatment
TT - surgical correction called tarsotomy
CO - may benefit from corneal transplant

Trachoma control

SAFE strategy

It stands for

Surgery – Trichiasis surgery

Antibiotics – Tetracycline ointment, Systemic tetracycline or Doxycyclin

It may be given on a community or individual basis

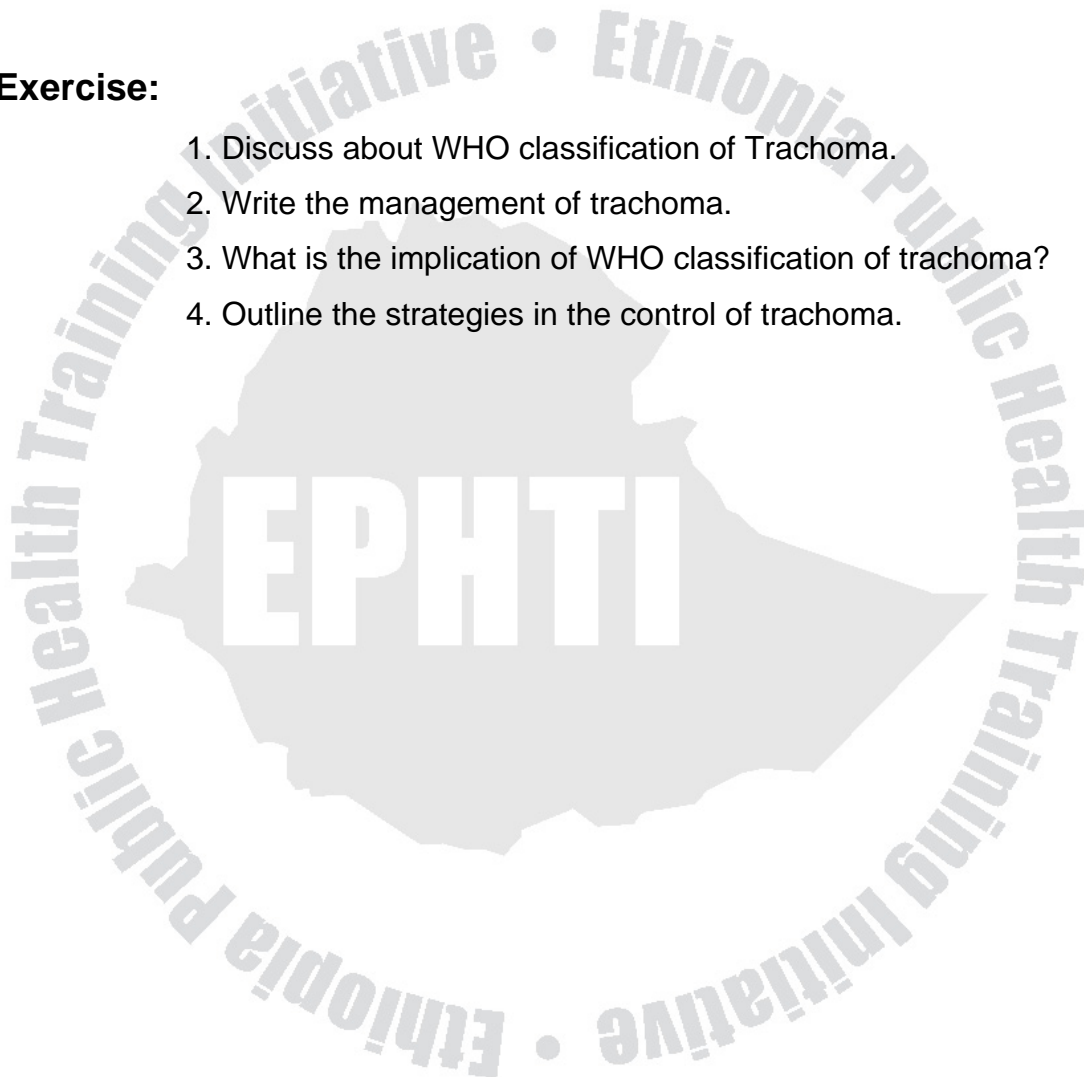
Face washing – regular face washing to keep the eyes and face clear of discharge, health education

Environmental change—provide adequate water supply, improve community sanitation (building and using VIP latrines and proper waste disposal); exclude cows and goat from the home.

For community treatment of trachoma, mass distribution of tetracycline ointment is carried out especially during epidemics of conjunctivitis at intervals for five consecutive days per month for six months.

Exercise:

1. Discuss about WHO classification of Trachoma.
2. Write the management of trachoma.
3. What is the implication of WHO classification of trachoma?
4. Outline the strategies in the control of trachoma.



3. REFRACTIVE ERROR AND STRABISMUS

INTRODUCTION

Emmetropia:

The normal refractive state of the eye. The eye acts as a convex lens and parallel rays of light are focused on the retina. Light rays coming from 6 meter or more is considered to be parallel. For this reason during distance vision testing the patient is seated 6 meters from the test chart. Most of the refraction in the eye is done by the cornea (2/3) the rest being by the lens (1/3)

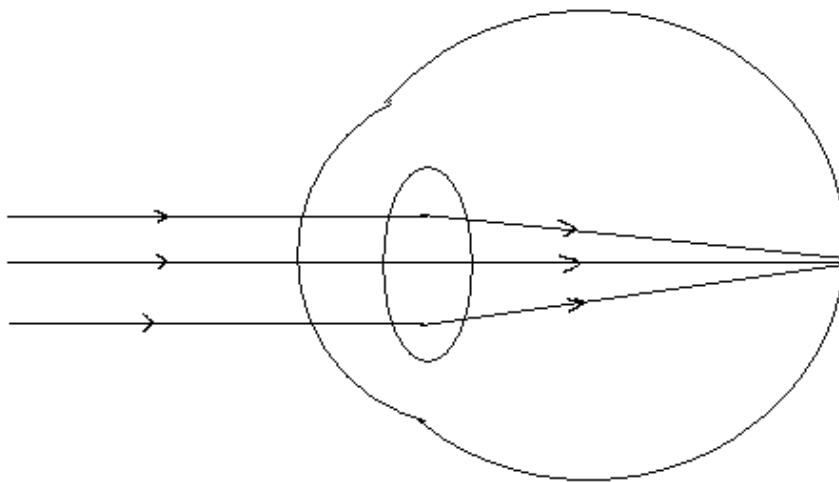


Fig 5.1. Refraction in a normal eye

Accommodation

Rays of light from an object close to the eye is divergent and will be focused behind the retina. The eye adjusts the image by:

- Contraction of ciliary muscles thereby loosens the suspensory ligaments so that the lens will be more spherical and strong.
- Decreasing the size of the pupil.
- Contraction of the medial recti.

All these muscles are innervated by Oculomotor nerve.

Refractive Errors

In states of refractive error rays of light cannot be focused on the retina and the image appears blurred.

The main types of refractive errors are

1. Myopia (short sightedness)

In myopic eye the refractive power is so high that parallel rays of light focused in front of the retina.

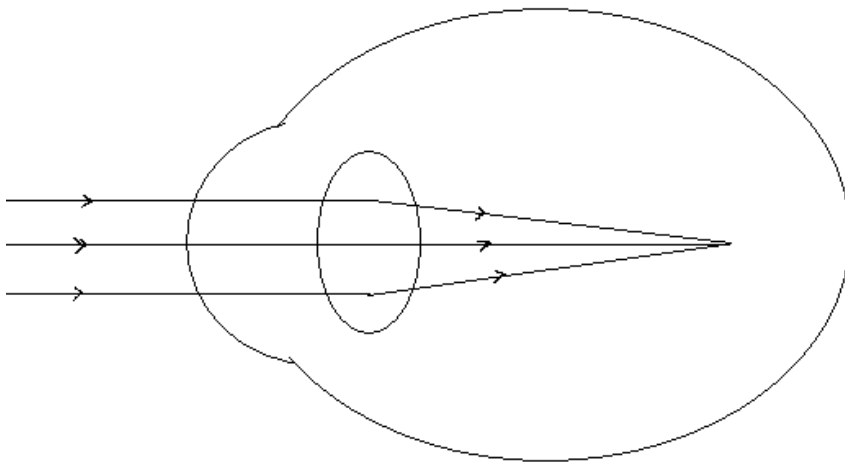


Fig 5.2.Refraction in myopic eye

Symptom

-Poor distant vision

Treatment

- Spectacle- concave or negative lens

2. Hypermetropia (long-sightedness)

In hypermetropia rays of light are focused behind the retina because the power of the optical system is too low for the length of the eye.

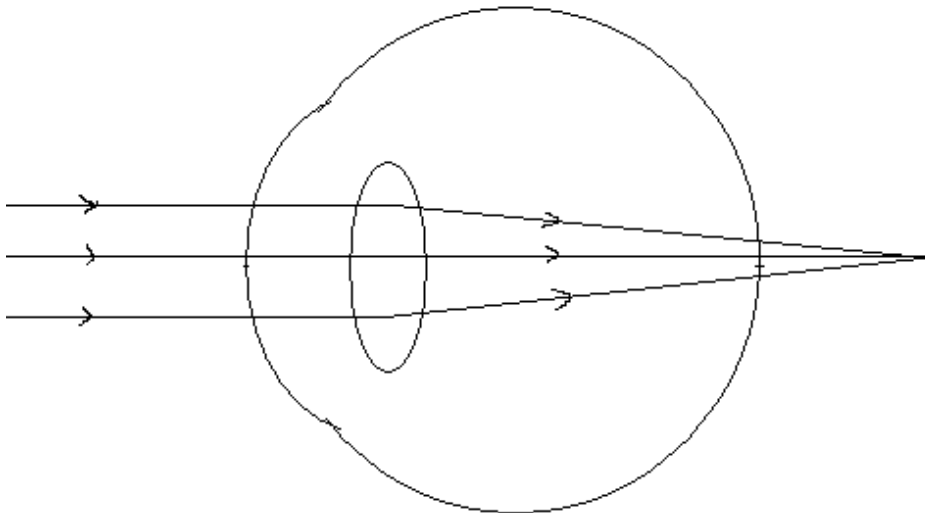


Fig 5.3. Refraction in hypermetropic eye

Symptoms

- Complain about near vision tasks
- In advanced state they will have poor distant vision

Treatment

- Convex lens or positive lens

3. Astigmatism

In astigmatism the rays of light coming to the eye are focused differently in different meridians or has two focal points.

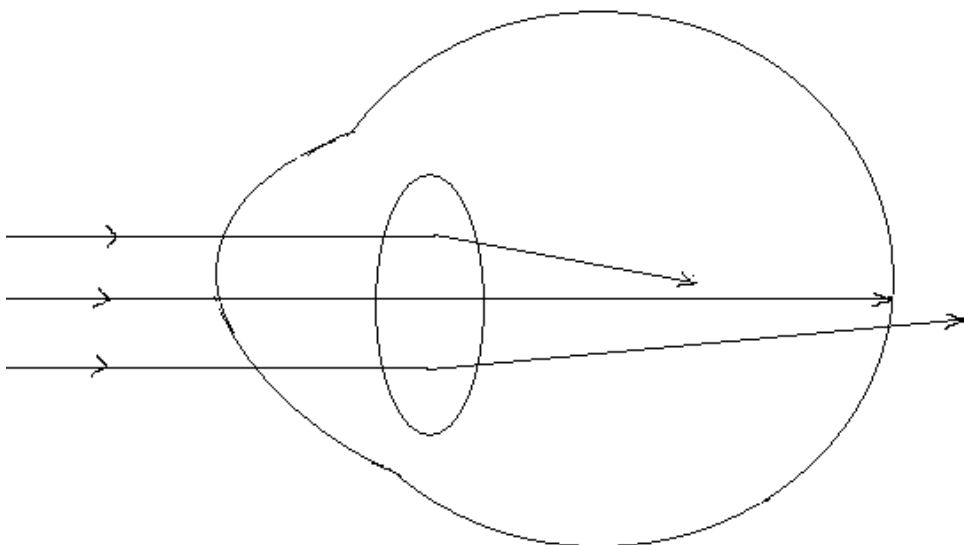


Fig. 5.4 refraction by an astigmatic eye

Symptom

- Distortion of image
- Poor vision at any distance

Treatment

- Spectacle with cylindrical lens

4. Presbyopia

This is the result of the natural aging process of the lens where it becomes harder and less elastic. Accommodation will be ineffective and the person fails to do near work like reading. There is no difficulty of distant vision.

Treatment-convex lens

5. Surgical Aphakia

This is an eye with lens removed surgically.

Treatment-spectacle with high positive lens

STRABISMUS

Definition- misalignment of eyes

Symptom

- Deviation of the eye
- Could have Diplopia
- Poor vision

Sign

- V/A may be normal or reduced
- Deviated eye

Types of strabismus

Medial deviation (esotropia)

Lateral deviation (exotropia),see color plate17

Upward (hyper tropic)

Down ward (hypotropic)

Treatment

Early detection and referral for

- Amblyopia treatment
- For spectacle and/or surgery

Amblyopia (lazy eye)

Definition: a reduction of vision of one or both eyes despite normal ocular finding.

Causes

- certain types of refractive error
- Strabismus
- sensory e.g. cataract, Ptosis

Treatment

- Early referral to better center

Exercise:

1. What is the difference between Presbyopia and hypermetropia?
2. Does short sight ness get better when age increase?
3. What are the components of accommodations?

4. CHILDHOOD BLINDNESS

Introduction

The current estimate suggests that there are 1.4 million children blind globally , 22.9% live in sub Saharan Africa making a total number of 320,000 blind children in that part of the world. Many of the causes of blindness in children are also a cause of child mortality(e.g. measles, Vitamin A deficiency, congenital rubella syndrome, cerebral malaria ,head injuries, tumors).This means that many children who become blind die within a few years of becoming blind. As the prevalence of blindness is a measure of those blind children who survive. It underestimates the magnitude of the problem.

4.1.Vitamin A Deficiency Disorder (VADD)

Def'n :It is change in the eye and other systems from vitamin A deficiency.

1. Dietary sources of retinol

Animal foods

- contain the active vitamin retinol
- liver is the best source which stores retinol
- milk products are also very rich in retinol

Plant foods

- are particularly important because they are the staple diet for poor people
- Contain carotene pigment which is converted into retinol
- The best source is red palm oil others carrots, mangoes, papaya
- poor sources rice, cassava, yams, and white maize which are staple diet of the poor

2. Function of vitamin A

- .main function is maintenance of healthy epithelium
- .formation of visual purple

3. Clinical signs and symptoms

1. XN -Night blindness

- poor dark adaptation and poor night vision (nyctalopia)
- is the earliest symptom of vitamin A deficiency

2. X1A- conjunctival xerosis

- Dryness of the conjunctiva causes to lose its normal shiny luster and look like wax or paint instead
- With treatment it is reversible

3. X1B -Bitot's spot with conjunctival xerosis(see color plate 11)

- Bitot's spot is a foamy plaque on the temporal aspect of bulbar conjunctiva

4. X2 -corneal xerosis

- Corneal surface looks rough, dull and irregular

5. X3A-corneal ulceration with xerosis

- The ulcers are bilateral and central

6. X3B-keratomalecia liquefaction of part of cornea

7. XS-Xerophthalmia scar

- Bilateral, central or lower part of cornea-It is the last and severe sign with melting of the cornea

8. XF-Xerophthalmia fundus

- A pale yellow spot appear near the course of retinal vessels and also in the retinal periphery..

Treatment Indications

- ↘ All children with any active corneal ulceration.
- ↘ All children with signs of Xerophthalmia
- ↘ All children with measles since they are prone to develop Xerophthalmia
- ↘ All severely ill or malnourished children from areas where Xerophthalmia occurs, even if there is no clinical evidence of Xerophthalmia.

Exercise:

1. What are the dietary sources of vitamin A?
2. What is the function of vitamin A?
3. What are the clinical signs of Vitamin A deficiency?
4. Outline the management of vitamin A depending on the age of a patient.
5. How are you going to prevent vitamin A deficiency?



4.2 Congenital cataract

Definition

Cataract noticed at birth.

Etiology

- congenital infection (TORCH)
- Trauma or anoxia at birth
- Genetic disorders

Clinical features

- whitish Pupillary reflex
- increased eye movement (nystagmus)

Treatment

- Early referral for surgical management. It is due to a fear of amblyopia.

4.3. Congenital glaucoma

Cause: mal development of trabeculum including iridocorneal junction

Symptoms

Triad of

- Epiphora
- Photophobia
- Blepharospasm

Signs

Triad of-

- Megalocornea (buphthalmos)
- Haab's striae (descemet membrane break)
- IOP > 20mm Hg (see color plate 16)

Treatment

Early referral for surgical management

5. GLAUCOMA

Def'n: It is commonly defined as a condition in which the intra ocular pressure is sufficiently high to cause optic nerve damage followed by visual field changes.

Glaucoma is broadly classified as

1. Open angle glaucoma
- 2 closed angle glaucoma. (It is discussed in chapter four)

PRIMARY OPEN ANGLE GLAUCOMA

It is characterized by

- Adult onset of age above 40 years
- Repeated IOP > 21mmHg
- Bilateral but severe in one eye

Symptoms

- Usually asymptomatic
- In advanced cases, there will be constriction of visual fields

Signs

- V/A is reduced in advanced case
- IOP is raised
- Visual field constriction
- Optic disc cupping

Treatment

Urgent referral for medical and surgical treatment.

Exercise:

1. Define Glaucoma
2. What is the normal range of IOP?
3. What are the clinical features and feared complication of congenital cataract?

UNIT SIX

EYE INJURIES

Objective:

1. To provide the students basic knowledge about different types of eye injuries
2. To give basic concepts on how to suspect, diagnose and act early.
3. At the end of the course the students are expected to diagnose and refer early eye injuries to the ophthalmic centre.

1. Foreign body

- Can be on the conjunctiva or cornea
- Can be metallic or non metallic
- The most common eye injury

Conjunctival foreign body

- . Mostly found on the upper tarsal conjunctiva
- . It is good to check for FB by everting the upper lid
- . Need illumination and remove it by a cotton tip
- . Irrigate with normal saline or tap water if foreign body can not be traced

Corneal foreign body

- . Can be on the surface or embedded in the cornea
- . Patient complains of pain and foreign body sensation
- . Use adequate light to visualize it(*see color plate 2*)

Treatment

- . Superficial foreign body can be removed either with cotton tipped or irrigation.
- . Topical antibiotic, Chloramphenicol eye drop QID for 7days
- . Eye pad for 24 hrs. -to give time for the epithelium to regenerate
- . If it fails early referral is indicated

2. Laceration

Eye lid laceration-

- clean the wound

- TAT
- topical eye ointment
- patch
- refer early because it needs to be repaired in three layers and with special sutures.

Conjunctival laceration

Usually self healing but if it is large(>1cm) it needs referral for suturing with special suture.

Conjunctival hemorrhage

Bleeding beneath the conjunctiva

Causes -trauma

-Spontaneously

Treatment

Self limiting, hemorrhage will resolve approximately within two weeks

3. Chemical burn

- Irritation of the eye because of accidental entry of a chemical is a common problem among factory workers
- A various types of acids and alkali are incriminated
- Patients have marked pain with tearing, photophobia and blepharospasm. - Conjunctiva may be red and chemotic with sites of ulceration. Cornea may be edematous and hazy or opaque

Treatment

- Copious irrigation with water immediately after the incident
- Removal of particulate material from the Conjunctival sac
- Prophylactic topical antibiotics
- Cycloplegic agent to relieve pain

4. Non penetrating or blunt eye ball injuries

It can be by a thrown object or a fist

Associated finding in the eye lids would be bruise and /or hemorrhage

Complication

- . Hyphema – blood in the anterior chamber
Treatment: patching, semi sitted position and early referral
- . Suspensory ligament rupture leads to Subluxation or dislocation of lens
- . Delayed cataract due to concussion damage of lens cells
- . Concealed eyeball rupture

5. Penetrating eye injuries

-by sharp object or fragment(see color plate 13)

Sign

- V/A reduced
- Hyphema
- Uveal tissue prolapsed
- Distorted pupil
- Shallow or flat anterior chamber
- Corneal tear
- Hypopyon

Treatment

- Ocular emergency
- Eye pad and/or eye shield
- systemic antibiotics ciprofloxacin 500 mg po BID for 7 days if not available
Chloramphenicol 500 mg p. o QID for 7 days.
- T.A.T
- Don't apply topical eye drops or ointment
- Urgently refer to ophthalmic center for surgical management

Complication

- Corneal scar
- Cataract
- Endophthalmitis
 - is intra ocular infection
- Sympathetic ophthalmitis
 - is rare but serious complication
 - it affects the normal eye because of immunologic reaction

Exercise:

1. What is the clinical feature of a patient with corneal foreign body?
2. Outline the management of a patient with penetrating eye injuries.
3. What is the complication of a patient with untreated penetrating eye injuries?
4. How are you going to manage a patient who came to you having chemical injury eyes?



UNIT SEVEN

SYSTEMIC DISEASES AND THE EYE

Objective: -

1. To give the students introductory concept on systemic disease affecting the eye.
2. At the end of the course, students are expected to consider one or more ophthalmic manifestation for most of systemic disease that will range from mild self limiting to severe sight threatening condition.

Most systemic diseases have one or more ophthalmic manifestation that ranges from mild self limiting to sight threatening conditions. Under this chapter some of the commonest systemic diseases will be discussed.

A. DIABETES MELLITUS

Definition: diabetes is a metabolic disorder with hyperglycemia due to peripheral tissue resistance to insulin action or failure of insulin secretion or both that leads to micro vascular and cardiovascular complications.

Ophthalmic manifestation of diabetes mellitus

1- Diabetic retinopathy

It is a disorder of the retinal vasculature that eventually develops to some degree in nearly all patients with longstanding diabetes mellitus.

Pathogenesis

The cause of diabetic micro vascular disease is unknown. It has been suggested that exposure to hyperglycemia over an extended period of time results in ultimate vascular damage which is a micro-angiopathy of retinal vessels that result in micro vascular occlusion and leakage. Micro vascular occlusion will cause hypoxia of the retina and stimulate new blood vessel formation. These vessels are fragile and bleed easily.

Epidemiology

It is the leading cause of legal blindness in developed world. The situation is increasing in our country.

Risk factors

Duration of diabetic mellitus

Age of onset

Blood glucose control

Co morbid illness like pregnancy, hypertension, renal diseases smoking etc

Clinical symptoms and signs

- Normal or reduced vision
- Retinal findings include exudates, hemorrhage, new vessel formation

Management

Strict blood glucose control

Avoid risk factors

Refer to ophthalmic center for evaluation

Follow up

2-Diabetic cataract

3- Others- refractive error, cranial nerve palsy, Neovascular Glaucoma

B. HYPERTENSION

Definition: an acute or chronic elevation of systemic blood pressure leading to characteristic ophthalmoscopic alteration over the fundus and other systemic complications.

Hypertensive retinopathy

It will have retinal vascular change with arterial thickening, leakage and hemorrhage over the fundus.

Symptoms

Normal or reduced vision

Nausea

Headache

Vomiting

Signs

Normal or reduced V/A

Elevated blood pressure

Vascular thickening, exudates, hemorrhages, papilledema etc on the retina

Management

Control of blood pressure

Refer to ophthalmic center for better evaluation

C.HIV/ AIDS AND THE EYE

HIV/AIDS is a disease caused by the human immune deficiency virus/HIV/. Patients will have recurrent opportunistic infections or of unusual tumors in association with a dysfunctional cellular system. HIV has been demonstrated in tears, conjunctival epithelial cells, corneal epithelial cells, aqueous, retinal vascular endothelium, and retina.

Ophthalmic manifestation is classified as

1. Microvasculopathy
2. Tumor e.g. Kaposi's sarcoma, Squamous cell carcinoma
3. Neuro-ophthalmopathy e.g. cranial nerve palsy, optic atrophy
4. Opportunistic infection e.g. herpes zoster ophthalmicus, herpes simplex infection, toxoplasmosis etc

Over 70% of AIDS cases have some form of ophthalmic manifestation.

Some of the commonest diseases will be discussed.

1. Ophthalmic herpes zoster

- is caused by varicella zoster
- eye is affected through ophthalmic branch of trigeminal nerve.
- Unilateral
- Common in immunocompromized patient
- 90% are sero positive for HIV infection and most are young

Symptoms

- prodromal symptoms of URTI

- the rash appears 2-3 days after the pain, the rash is not different in sero positive and sero negatives but recurrent in sero positives

Signs – in chronological order

1. Maculopapular rash in the forehead
2. Development of vesicles, pustules and crusting ulceration
3. In severe cases – periorbital edema due to secondary bacterial cellulitis. (see color plate 18)

It can also cause Keratitis, Uveitis, Keratouveitis, cataract, vitritis etc

Treatment

- analgesics
 - Aspirin 600mg Q4hr.
 - Paracetamol 1gm Q4hr
- *Gentian violet*– 0.5% to clean the wound
- *Topical antibiotics to the eye*
- Antiviral
 - *Systemic*
 - Should be given within 72 hrs after rash because the drug needs active viral replication
 - Acyclovir 800mg 5x/day/for 7days
 - Refer to ophthalmic center for further evaluation.

2. Molluscum contagiosum

- In immunocompromized patient, it is multiple, large size, bilateral, recurrent and resistant to treatment.

Symptom – painless, raised, skin lesion.

Sign

- single or multiple
- Pale, waxy
- umbilicated nodules
- If the nodule is located on the lid margin it may give rise to ipsilateral chronic follicular conjunctivitis and occasionally a superficial keratitis

Treatment

- Expression
- shaving and excision
- destruction of the lesion by cauterization, cryotherapy

3. Squamous Cell Carcinoma

- a malignant neoplasm of keratinizing cells of the epidermis.
- high chance to metastasize

Symptoms and signs

- Painless plaque or nodule with variable degree of scale, crust and ulceration

Treatment

- Referral for surgical excision and biopsy

4. Kaposi's Sarcoma

a malignant vascular tumor that develops on the skin, mucous membrane, lymph node and visceral organs. It appears like flat or raised non tender , purple red -dark reddish lesion over the eye lid or conjunctiva.

Referral for surgical excision and biopsy.

5. Uveitis

- Caused by - herpes simplex
- Herpes zoster
 - Toxoplasmosis

6. HIV retinopathy

It is a non-infectious micro vascular disorder characterized by cotton wool spots, microaneurysm, retinal hemorrhages, and area of capillary non-perfusion. These micro vascular changes are the most common retinal manifestations of HIV disease and are clinically apparent in about 70% of persons with advanced HIV disease.

7. Cranial nerve palsy

If the third, fourth, or sixth nerves are affected, there will be diplopia. If optic nerve is affected, there will be loss of vision.

Causes : CMV or other infections

Diagnosis

- serology (ELISA)for HIV
- Clinical

Treatment

- Treatment of opportunistic infection accordingly
- Antiretroviral drugs
- Health education about the syndrome

D. OTHERS

Collagen/vascular disease

Rheumatoid arthritis

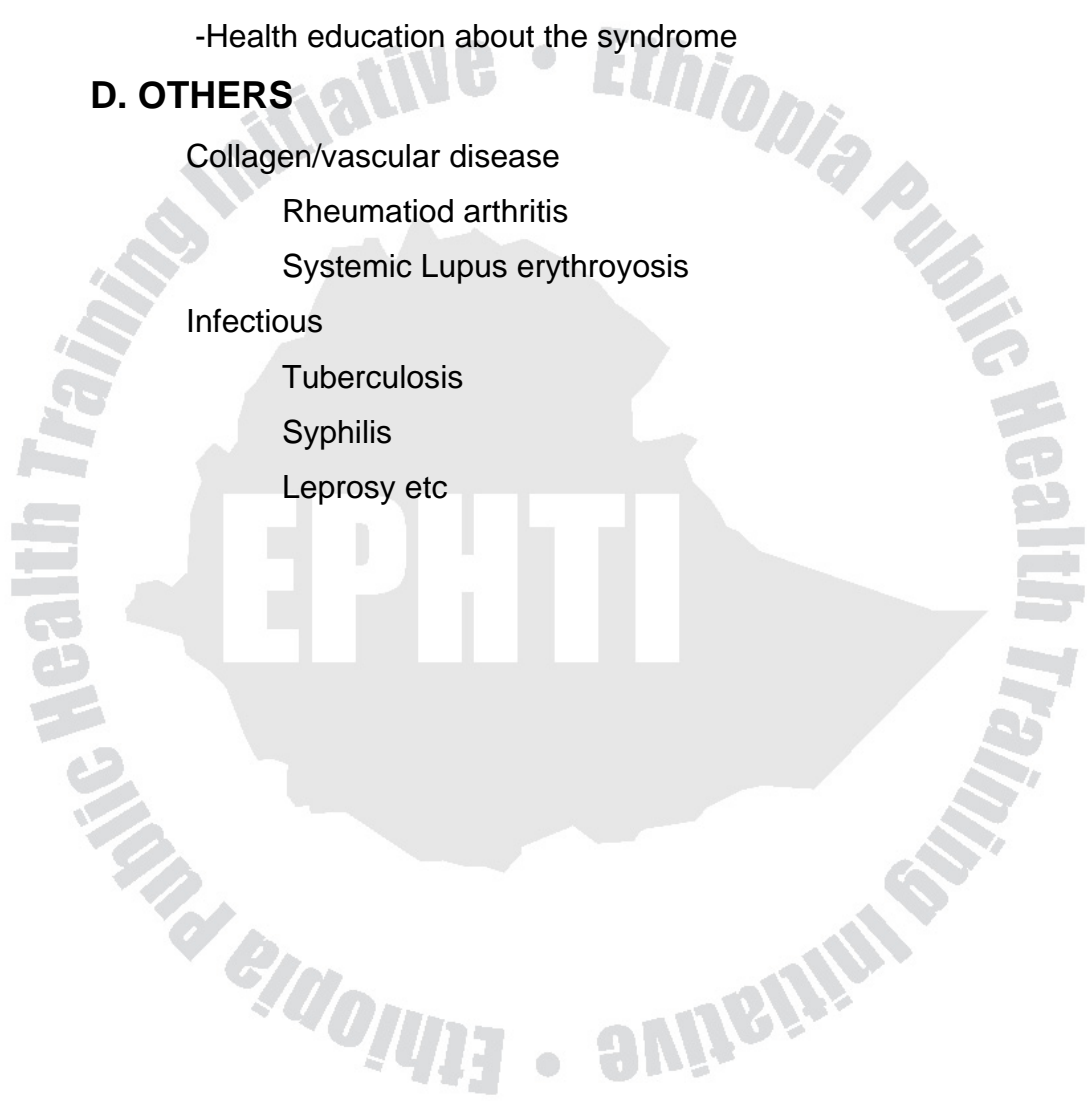
Systemic Lupus erythroyosis

Infectious

Tuberculosis

Syphilis

Leprosy etc




Exercise:

1. What are the ophthalmic manifestations of HIV?
2. What are ophthalmic manifestations of diabetes mellitus?

Reference

- 1- John sand ford – smith, **Eye Disease In Hot Climate** c reed Educational and professional publishing LTD ,1997
- 2- J. kanski **Clinical Ophthalmology** c reed Educational and professional publishing LTD 1999
- 3- Kenneth W.wright ,**A Text Book Of Ophthalmology** c Williams and wilkins 1997
- 4- Albert and Jakoboiec**Principle and practice of ophthalmology**
- 5- **Up to date** - (C) 2001 - www.up to date.com.(800) 998-6374.(781)237-4788



APPENDIX

I-Eye Preparations

Drugs are prepared in the form of drops, ointment or suspensions. These forms are more effective for the front of the eye, the conjunctiva, cornea, anterior chamber and iris.

Drops are the most convenient and common way of giving topical treatment to the eye. If high levels of the drug need to be maintained, the drops must be applied frequently.

Ointments stay longer in contact with the eye, and are more often used at night. They generally blur vision and are messy than drops.

Side effects of steroids

1. Cataract
2. Glaucoma
3. Corneal thinning
4. Predispose to infection by reducing local immunity

Contra indication of steroids

1. Infection of the eye
2. Corneal ulcer
3. Glaucoma

II-Primary eye care training material

A. Equipment and supplies

- Snellen's E- chart
- Reading chart
- Occluder
- Pinhole
- Torch
- 2.5X magnifying loupe
- Scissors
- Tonometer
- Syringe and needle
- dressing, gauze rolls, cotton roll, eye pads and bandage
- ophthalmoscope

B. Drugs

- Tetracycline eye ointment
- Chloramphenicol eye drop or ointment
- Gentamycin
- Diamox, Timolol, dexamethasone
- Local anesthesia- tetracaine 1%

III. How to apply eye medication

- explain to the patient what is to be done
- read the instruction on the eye drop/ointment carefully and sit the patient with the head tilted back.
- ask the patient to keep both eyes open, look up and hold his/her head back
- Gently pull down the lower eyelid so that you can see the conjunctiva
- squeeze out a small amount of ointment or drop and release one drop of the drop in to one third of the lower conjunctiva.
- If one is to use both drops and ointment one has to apply drops first to be followed by ointment.
- don't allow the tip of the ointment or drop container to touch the eyelid or the eye in order to avoid contamination
- order the patient to close the eyes for about a minute or two to allow drug absorption.
- clean up the excess drop or ointment on the lid with a cotton/gauze swab
- recap the bottle or tube with out contaminating

IV. Making and Applying an Eye Pad

- Cut the cotton and gauze rolls
- Place layers of gauze on the working bench or table
- Place a thick cotton layer on top of the gauze
- Further place another layer of gauze on top of the cotton
- This makes a three layered patch: gauze-cotton wool-gauze
- Cut the patch in to smaller patches and trim it with scissor to make it oval.

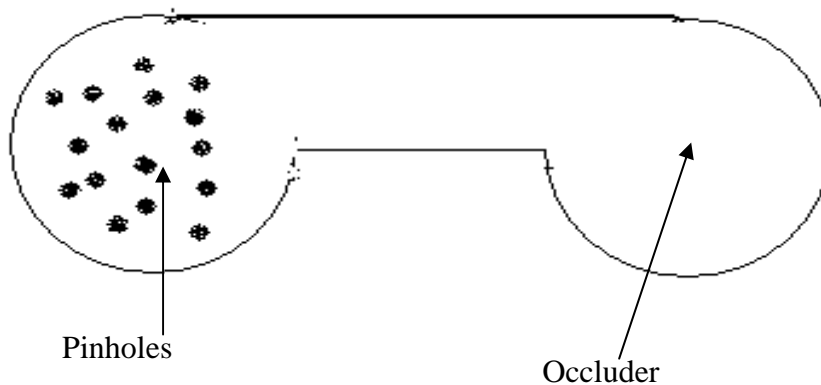
- Ask the patient to close the eye lid
- Apply the patch or pad over the closed eye with adhesive plaster obliquely

V. Making and Applying a Protective shield

- Trace the edge of a drinking cup or gally pot on card board or x-ray film
- Cut a circle of thin card from the card board or used x- ray film from the traced and make a cut to the center of the circle or tip of the fold using one of the radius.
- Make it in to a cone
- Tape or glue together the outside and inside edges
- Tape over the patient's injured eye
- Make sure that the shield rests on the eyebrow and cheekbone; it should not rest on the eyeball.

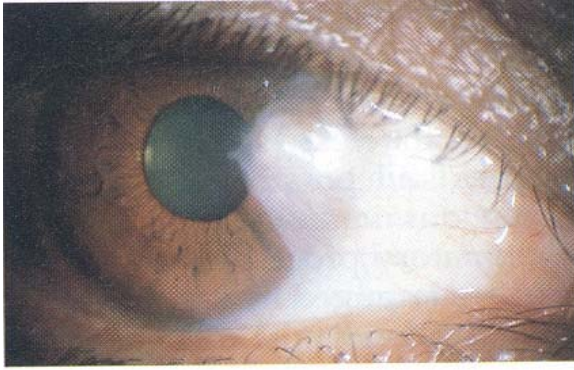
VI. Making an E card and occluder

- trace the occluder and the E card on the thick cardboard provided
- cut the outlined edges of the cardboard
- paste the two edges of the cut cardboard together and staple or glue together
- with the aid of a pin make multiple pin holes on one side of the occluder
- try using the occluder and the E card

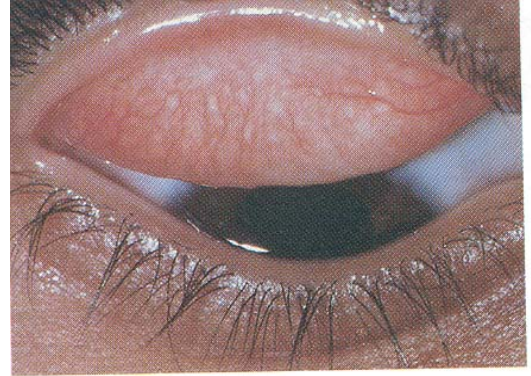


Reference

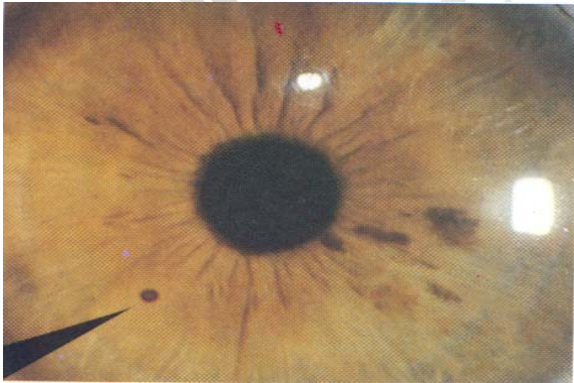
- 1 - John sand ford – smith, Eye disease in Hot Climate c reed Educational and professional publishing LTD ,1997
- 2 - J. kanski clinical ophthalmology c reed Educational and professional publishing LTD 1999
- 3 - Kenneth W.wright ,A text Book of ophthalmology - E. Ahmed
- 4 - Up to date - (C) 2001 - www.up to date.com.(800) 998-6374.(781)237-4788
- 5 - voghan Asbury: General ophthalmology
- 6 - A Bedford: A color Atlas of ophthalmologic Diagnosis –Wolfe
- 7 - chwab L. Primary eye care in developing Nations- Oxford
- 8 - Erika Sutter, Allen foster and Victoria Francis: Hanyane, A village struggles for eye health
- 9 - WHO: Management of trachoma in the community
- 10 -WHO: Trichiasis surgery for trachoma, 1993
- 11 -WHO: management of cataract in primary health care, 1990
- 12 -WHO: Field Guide to detection and control of xerophthalmia,1982
- 13 -WHO: prevention of childhood blindness, 1992
- 14 -WHO: Guidelines for Programmes for the prevention of blindness,1979
- 15 -WHO: Strategies for the prevention of blindness in National programmes,1984
- 16 -WHO: Primary Eye care, 1978
- 17 - WHO/PBL/95.48 Assessment of low vision in Developing countries
- 18 - ICEH “Journal- Community Eye Health”
- 19 - ICEM Book/Slide set
 - I- Examination of the eye
 - II- The eye in primary Health care
 - III- Cataract
 - IV- Childhood Blindness
 - V- Trachoma
- 20- WHO Book/Slide: The child, measles and the eye
- 21- Sand ford smith: Eye Surgery in Hot Climate; 2nd Edition, 2001.



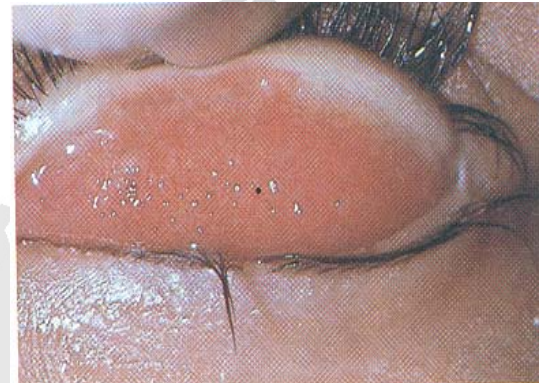C.P.1.Pterygium



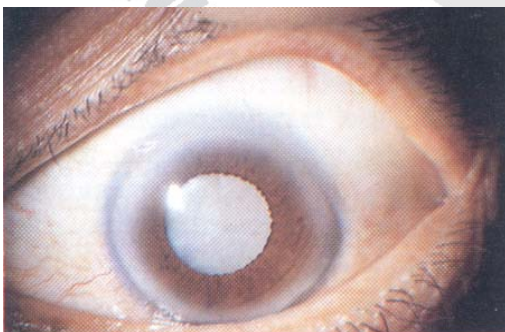C.P.4.Mild trachoma with follicle and papilla



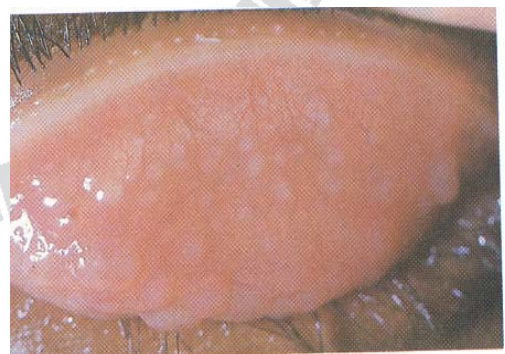
C.P.2.Corneal foreign body indicated by the arrow



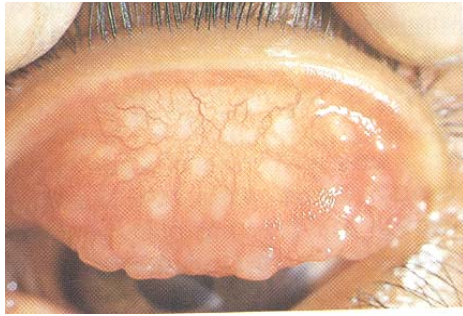C.P.5. severe active trachoma with follicle and papilla



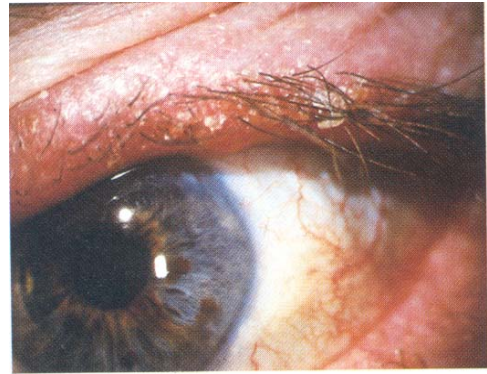C.P.3. Mature cataract



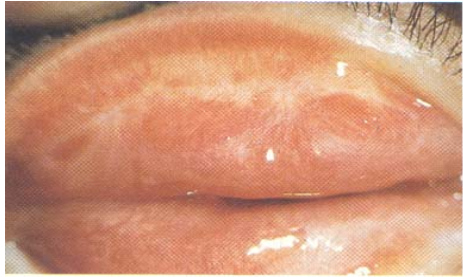C.P.6.Moderate active trachoma with follicle and papilla



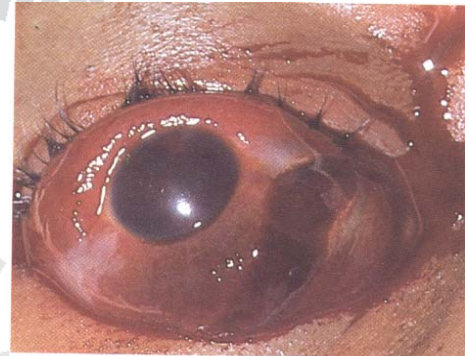
C.P.7.big papilla and follicles



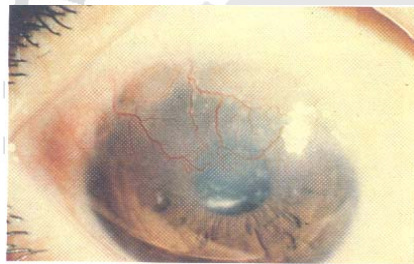
C.P.12. blepharitis



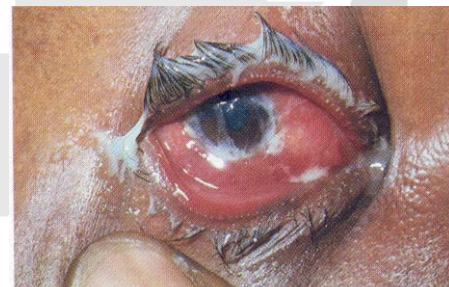C.P.8. Conjunctival scar in the upper tarsal conjunctiva



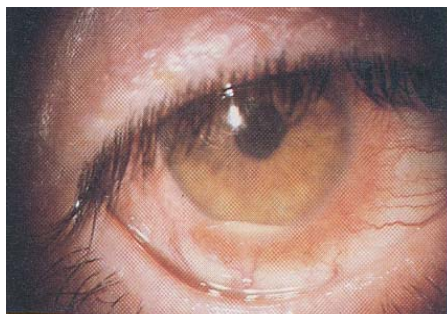C.P.13. Penetrating eye injuries with scleral laceration



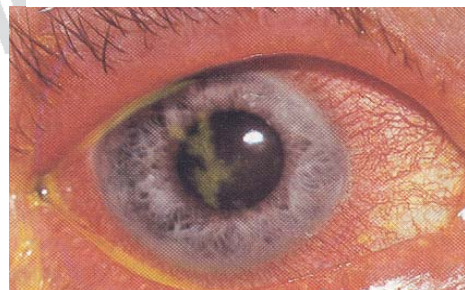C.P.9. Corneal vascularization and scar



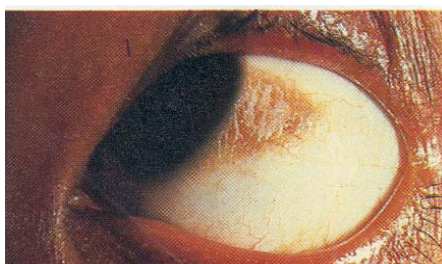
C.P.14 .Bacterial conjunctivitis



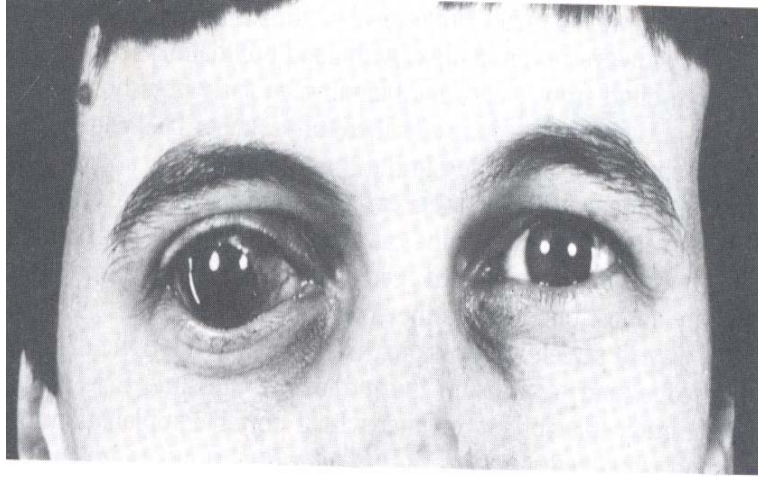C.P.10. Acute iridocyclitis



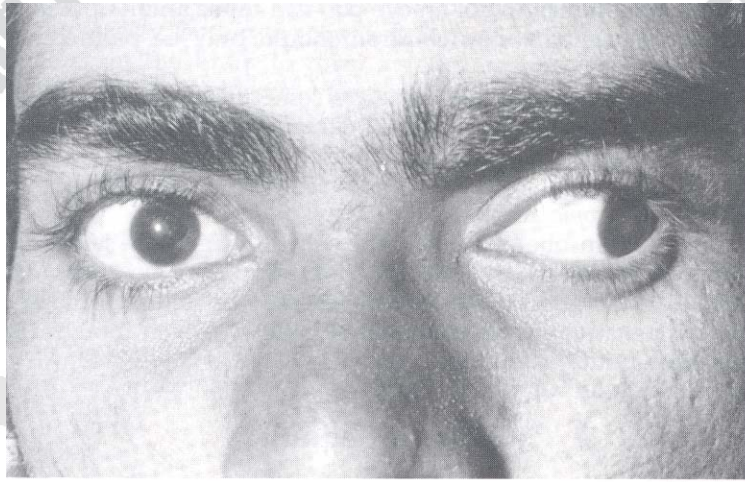
C.P.15. keratitis



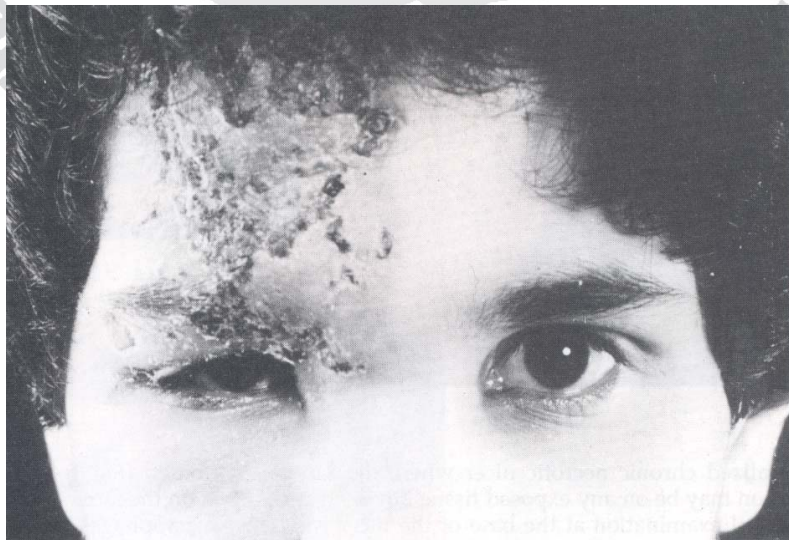C.P.11.Bitot's spots with conjunctival xerosis



C.P.16 congenital glaucoma



C.P.17 left eye exotropia



C.P.18. Ophthalmic Herpes zoster